

1

Clinical Significance of Dental Anatomy, Histology, Physiology, and Occlusion

LEE W. BOUSHELL, JOHN R. STURDEVANT

A thorough understanding of the histology, physiology, and occlusal interactions of the dentition and supporting tissues is essential for the restorative dentist. Knowledge of the structures of teeth (enamel, dentin, cementum, and pulp) and their relationships to each other and to the supporting structures is necessary, especially when treating dental caries. The protective function of the tooth form is revealed by its impact on masticatory muscle activity, the supporting tissues (osseous and mucosal), and the pulp. Proper tooth form contributes to healthy supporting tissues. The contour and contact relationships of teeth with adjacent and opposing teeth are major determinants of muscle function in mastication, esthetics, speech, and protection. The relationships of form to function are especially noteworthy when considering the shape of the dental arch, proximal contacts, occlusal contacts, and mandibular movement.

Teeth and Supporting Tissues

Dentitions

Humans have primary and permanent dentitions. The primary dentition consists of 10 maxillary and 10 mandibular teeth. Primary teeth exfoliate and are replaced by the permanent dentition, which consists of 16 maxillary and 16 mandibular teeth.

Classes of Human Teeth: Form and Function

Human teeth are divided into classes on the basis of form and function. The primary and permanent dentitions include the incisor, canine, and molar classes. The fourth class, the premolar, is found only in the permanent dentition (Fig. 1.1). Tooth form predicts the function; class traits are the characteristics that place teeth into functional categories. Because the diet of humans consists of animal and plant foods, the human dentition is called *omnivorous*.

Incisors

Incisors are located near the entrance of the oral cavity and function as cutting or shearing instruments for food (see Fig. 1.1). From a proximal view, the crowns of these teeth have a relatively triangular shape, with a narrow incisal surface and a broad cervical base. During mastication, incisors are used to shear (cut through) food.

Incisors are essential for proper esthetics of the smile, facial soft tissue contours (e.g., lip support), and speech (phonetics).

Canines

Canines possess the longest roots of all teeth and are located at the corners of the dental arches. They function in the seizing, piercing, tearing, and cutting of food. From a proximal view, the crown also has a triangular shape, with a thick incisal ridge. The anatomic form of the crown and the length of the root make canine teeth strong, stable abutments for fixed or removable prostheses. Canines not only serve as important guides in occlusion, because of their anchorage and position in the dental arches, but also play a crucial role (along with the incisors) in the esthetics of the smile and lip support.

Premolars

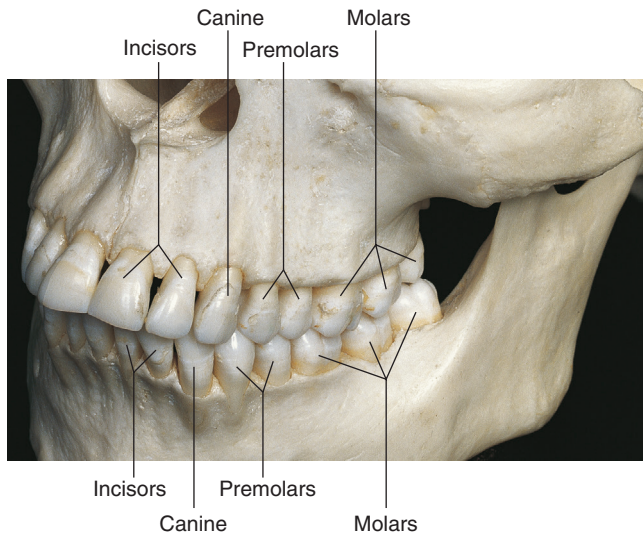
Premolars serve a dual role: (1) They are similar to canines in the tearing of food, and (2) they are similar to molars in the grinding of food. Although first premolars are angular, with their facial cusps resembling canines, the lingual cusps of the maxillary premolars and molars have a more rounded anatomic form (see Fig. 1.1). The occlusal surfaces present a series of curves in the form of concavities and convexities that should be maintained throughout life for correct occlusal contacts and function. Although less visible than incisors and canines, premolars still play an important role in esthetics.

Molars

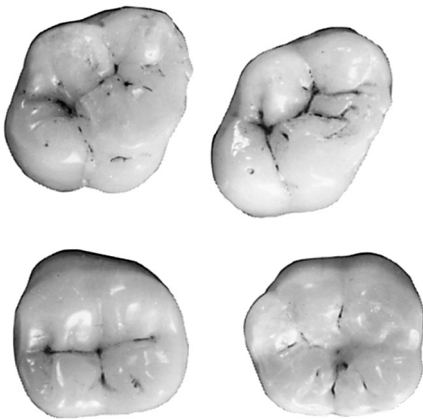
Molars are large, multicusped, strongly anchored teeth located nearest the temporomandibular joint (TMJ), which serves as the fulcrum during function. These teeth have a major role in the crushing, grinding, and chewing of food to dimensions suitable for swallowing. They are well suited for this task because they have broad occlusal surfaces and anchorage (Figs. 1.2 and 1.3). Premolars and molars are important in maintaining the vertical dimension of the face (see Fig. 1.1).

Structures of Teeth

Teeth are composed of enamel, the pulp–dentin complex, and cementum (see Fig. 1.3). Each of these structures is discussed individually.



• **Fig. 1.1** Maxillary and mandibular teeth in maximum intercuspal position. The classes of teeth are incisors, canines, premolars, and molars. Cusps of mandibular teeth are one half cusp anterior of corresponding cusps of teeth in the maxillary arch. (From Logan BM, Reynolds P, Hutchings RT: *McMinn's color atlas of head and neck anatomy*, ed 4, Edinburgh, 2010, Mosby.)

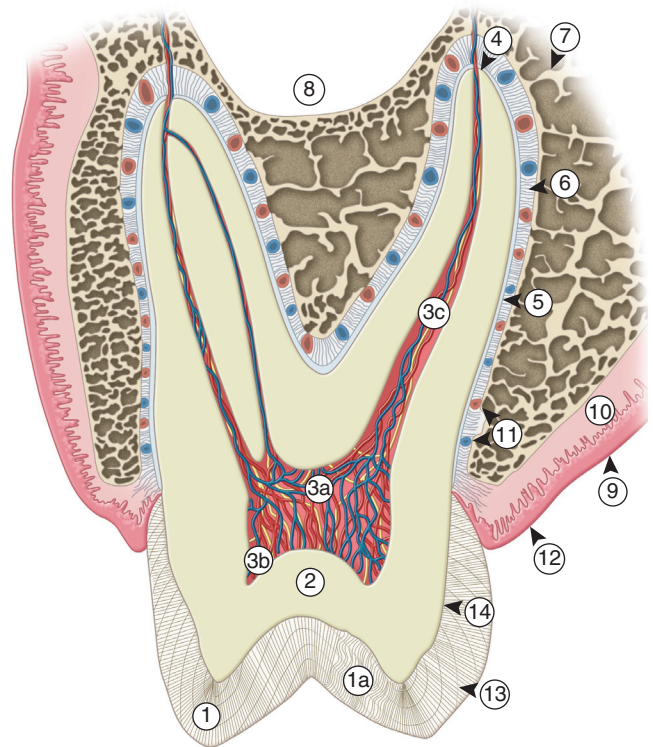


• **Fig. 1.2** Occlusal surfaces of maxillary and mandibular first and second molars after several years of use, showing rounded curved surfaces and minimal wear.

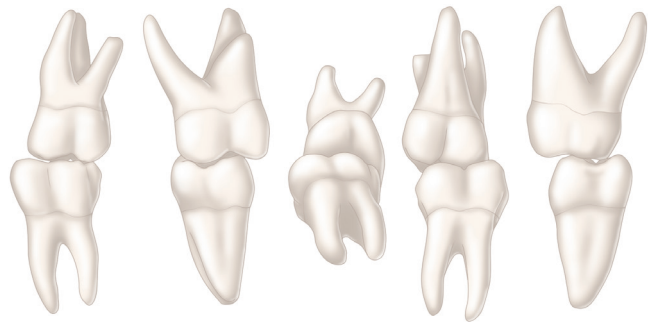
Enamel

Enamel formation, *amelogenesis*, is accomplished by cells called *ameloblasts*. These cells originate from the embryonic germ layer known as *ectoderm*. Enamel covers the anatomic crown of the tooth, varies in thickness in different areas, and is securely attached to the dentin by the dentinoenamel junction (DEJ) (see Fig. 1.3). It is thicker at the incisal and occlusal areas of the crown and becomes progressively thinner until it terminates at the cemento-enamel junction (CEJ). The thickness also varies from one class of tooth to another, averaging 2 mm at the incisal ridges of incisors, 2.3 to 2.5 mm at the cusps of premolars, and 2.5 to 3 mm at the cusps of molars.

Cusps on the occlusal surfaces of posterior teeth begin as separate ossification centers, which form into developmental lobes. Adjacent developmental lobes increase in size until they begin to coalesce. Grooves and fossae result in the areas of coalescence (at the junction of the developmental lobes of enamel) as cusp formation nears



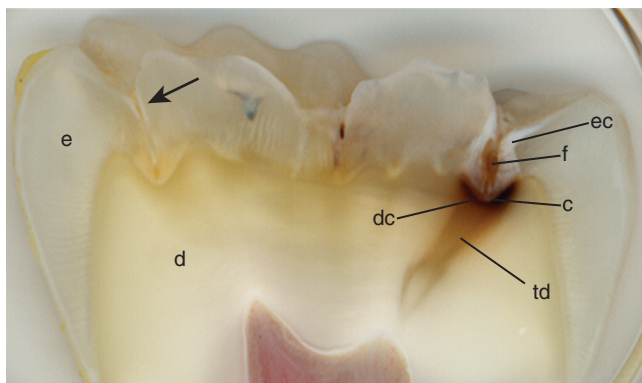
• **Fig. 1.3** Cross section of the maxillary molar and its supporting structures. 1, Enamel; 1a, gnarled enamel; 2, dentin; 3a, pulp chamber; 3b, pulp horn; 3c, pulp canal; 4, apical foramen; 5, cementum; 6, periodontal fibers in periodontal ligament; 7, alveolar bone; 8, maxillary sinus; 9, mucosa; 10, submucosa; 11, blood vessels; 12, gingiva; 13, lines of Retzius; 14, dentinoenamel junction (DEJ).



• **Fig. 1.4** Maxillary and mandibular first molars in maximum intercuspal contact. Note the grooves for escape of food.

completion. The strategic placement of the grooves and fossae complements the position of the opposing cusps so as to allow movement of food to the facial and lingual surfaces during mastication. A functional cusp that opposes a groove (or fossa) occludes on enamel inclines on each side of the groove and not in the depth of the groove. This arrangement leaves a V-shaped escape path between the cusp and its opposing groove for the movement of food during chewing (Fig. 1.4).

Enamel thickness varies in the area of these developmental features and may approach zero depending on the effectiveness of adjacent cusp coalescence. Failure or compromised coalescence of the enamel of the developmental lobes results in a deep invagination in the groove area of the enamel surface and is termed *fissure*. Noncoalesced enamel at the deepest point of a fossa is termed *pit*.



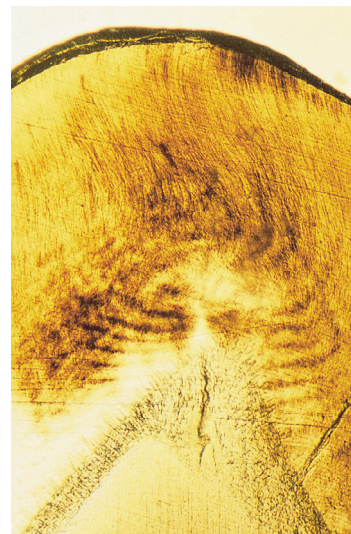
• **Fig. 1.5** Fissure (*f*) at junction of lobes allows accumulation of food and bacteria predisposing the tooth to dental caries (*c*). Enamel (*e*), dentin (*d*), enamel caries lesion (*ec*), dentin caries lesion (*dc*), transparent dentin (*td*); early enamel demineralization (*arrow*).

Fissures and/or pits represent non-self-cleansing areas where acidogenic biofilm accumulation may predispose the tooth to dental caries (Fig. 1.5).

Chemically, enamel is a highly mineralized crystalline structure. Hydroxyapatite, in the form of a crystalline lattice, is the largest mineral constituent (90%–92% by volume). Other minerals and trace elements are present in smaller amounts. The remaining constituents of tooth enamel include organic matrix proteins (1%–2%) and water (4%–12%) by volume.

Structurally, enamel is composed of millions of enamel rods (or “prisms”), rod sheaths, and a cementing interrod substance. Enamel rods, which are the largest structural components, are formed linearly by successive apposition of enamel in discrete increments. The resulting variations in structure and mineralization are called *incremental striae of Retzius* and may be considered growth rings that form during amelogenesis (see Fig. 1.3). The striae of Retzius appear as concentric circles in horizontal sections of a tooth. In vertical sections, the striae are positioned transversely at the cuspal and incisal areas in a symmetric arc pattern, descending obliquely to the cervical region and terminating at the DEJ. When these circles are incomplete at the enamel surface, a series of alternating grooves, called *imbrication lines of Pickerill*, are formed. Elevations between the grooves are called *perikymata*; they are continuous around a tooth and usually lie parallel to the CEJ and each other. Rods vary in number from approximately 5 million for a mandibular incisor to about 12 million for a maxillary molar. In general, the rods are aligned perpendicularly to the DEJ and the tooth surface in the primary and permanent dentitions except in the cervical region of permanent teeth, where they are oriented outward in a slightly apical direction. Microscopically, the enamel surface initially has circular depressions indicating where the enamel rods end. These concavities vary in depth and shape, and gradually wear smooth with age. Additionally, a structureless outer layer of enamel about 30 μm thick may be commonly identified toward the cervical area of the tooth crown and less commonly on cusp tips. There are no visible rod (prism) outlines in this area and all of the apatite crystals are parallel to one another and perpendicular to the striae of Retzius. This layer, referred to as *prismless enamel*, may be more heavily mineralized.

Each ameloblast forms an individual enamel rod with a specific length based on the specific type of tooth and the specific coronal location within that tooth. Enamel rods follow a wavy, spiraling course, producing an alternating clockwise and counterclockwise

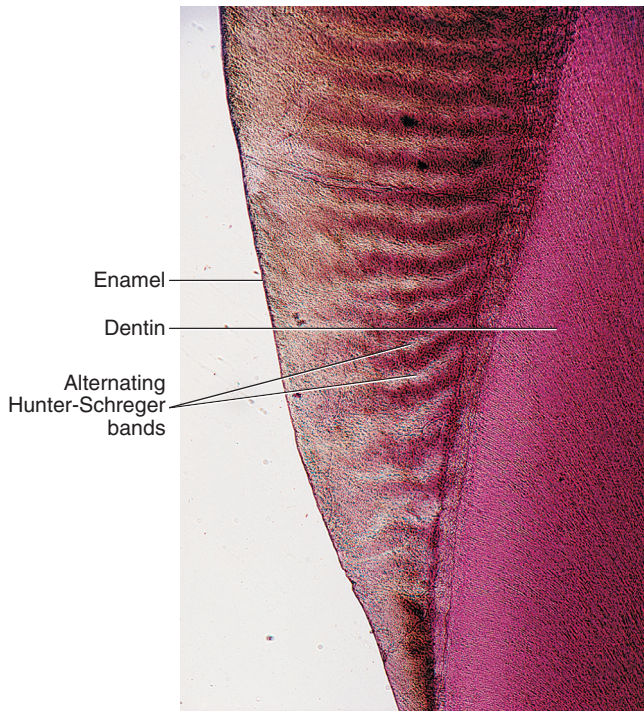


• **Fig. 1.6** Gnarled enamel. (From Berkovitz BKB, Holland GR, Moxham BJ: *Oral anatomy, histology and embryology*, ed 4, Edinburgh, 2009, Mosby.)

arrangement for each group or layer of rods as they progress radially from the dentin toward the enamel surface. They initially follow a curving path through one third of the enamel next to the DEJ. After that, the rods usually follow a more direct path through the remaining two thirds of the enamel to the enamel surface. Groups of enamel rods may entwine with adjacent groups of rods and follow a curving irregular path toward the tooth surface. These constitute *gnarled enamel*, which occurs near the cervical regions and also in incisal and occlusal areas (Fig. 1.6). Gnarled enamel is not subject to fracture as much as is regular enamel. This type of enamel formation does not yield readily to the pressure of bladed, hand-cutting instruments in tooth preparation. The orientation of the enamel rod heads and tails and the gnarling of enamel rods provide strength by resisting, distributing, and dissipating impact forces.

Changes in the direction of enamel rods, which minimize the potential for fracture in the axial direction, produce an optical appearance called *Hunter-Schreger bands* (Fig. 1.7). These bands appear to be composed of alternate light and dark zones of varying widths that have slightly different permeability and organic content. These bands are found in different areas of each class of teeth. Because the enamel rod orientation varies in each tooth, Hunter-Schreger bands also have a variation in the number present in each tooth. In anterior teeth, they are located near the incisal surfaces. They increase in numbers and areas of teeth, from canines to premolars. In molars, the bands occur from near the cervical region to the cusp tips. In the primary dentition, the enamel rods in the cervical and central parts of the crown are nearly perpendicular to the long axis of the tooth and are similar in their direction to permanent teeth in the occlusal two thirds of the crown.

Enamel rod diameter near the dentinal borders is about 4 μm and about 8 μm near the surface. This diameter difference accommodates the larger outer surface of the enamel crown compared with the dentinal surface at the DEJ. Enamel rods, in transverse section, have a rounded head or body section and a tail section, forming a repetitive series of interlocking rods. Microscopic ($\sim 5000\times$) cross-sectional evaluation of enamel reveals that the rounded head portion of each rod lies between the narrow tail portions of two adjacent prisms (Fig. 1.8). Generally, the rounded

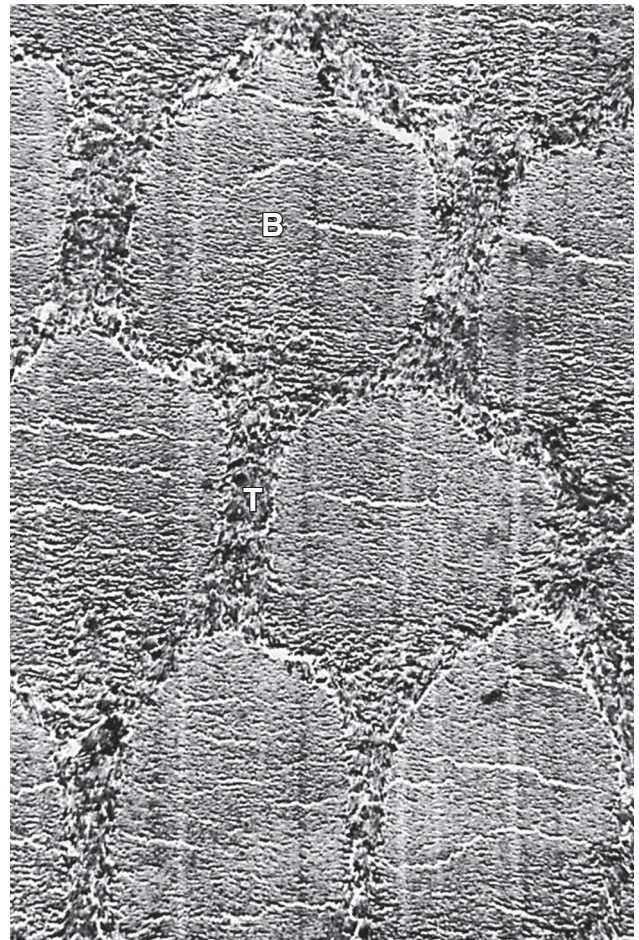


• **Fig. 1.7** Photomicrograph of enamel Hunter-Schreger bands. Photographed obtained by reflected light. (Modified from Chiego DJ Jr: *Essentials of oral histology and embryology: A clinical approach*, ed 4, St Louis, 2014, Mosby.)

head portion is oriented in the incisal or occlusal direction; the tail section is oriented cervically. The final act of the ameloblasts, upon the completion of enamel rod formation, is the secretion of a membrane layer that covers the ends of the enamel rods. This layer is referred to as *Nasmyth membrane*, or *primary enamel cuticle*. Ameloblasts degenerate upon completion of Nasmyth membrane, which covers the newly erupted tooth and is worn away by mastication and cleaning. The membrane is replaced by an organic deposit called the *pellicle*, which is a precipitate of salivary proteins. Microorganisms may attach to the pellicle to form a biofilm (bacterial plaque), which, if acidogenic in nature, may become a precursor to dental disease.

Each enamel rod contains millions of small, elongated apatite crystallites that vary in size and shape. The crystallites are tightly packed in a distinct pattern of orientation that gives strength and structural identity to the enamel rod. The long axis of the apatite crystallites within the central region of the head (body) is aligned almost parallel to the rod long axis, and the crystallites incline with increasing angles (65 degrees) to the rod axis in the tail region.

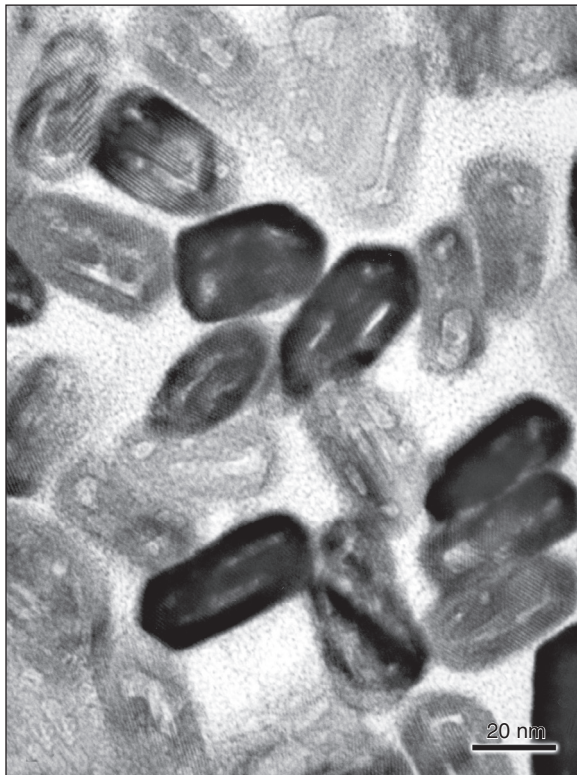
The susceptibility of these crystallites to acidic conditions, from the caries process or as a result of an etching procedure, may be correlated with their orientation. Acid-induced mineral dissolution (demineralization) occurs more in the head region of each rod. The tail region and the periphery of the head region are relatively resistant to acidic demineralization. The crystallites are irregular in shape, with an average length of 160 nm and an average width of 20 to 40 nm. Each apatite crystallite is composed of thousands of unit cells that have a highly ordered arrangement of atoms. A crystallite may be 300 unit cells long, 40 cells wide, and 20 cells thick in a hexagonal configuration (Fig. 1.9). An organic matrix surrounds individual crystals.



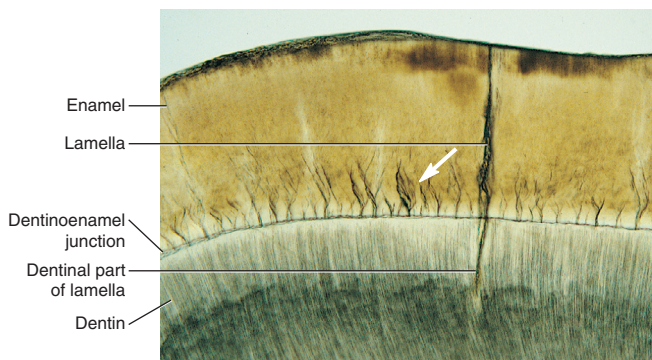
• **Fig. 1.8** Electron micrograph of cross section of rods in mature human enamel. Crystal orientation is different in “bodies” (B) than in “tails” (T). Approximate level of magnification $\times 5000$. (From Meckel AH, Griebstein WJ, Neal RJ: Structure of mature human dental enamel as observed by electron microscopy, *Arch Oral Biol* 10(5):775–783, 1965.)

Although enamel is a hard, dense structure, it is permeable to certain ions and molecules. The route of passage may be through structural units such as rod sheaths, enamel cracks, and other defects that are hypomineralized and rich in organic content. Water plays an important role as a transporting medium through the small intercrystalline spaces. Enamel tufts are hypomineralized structures of interrod substance between adjacent groups of enamel rods that project from the DEJ (Fig. 1.10). These projections arise in dentin, extend into enamel in the direction of the long axis of the crown, and may play a role in the spread of dental caries. Enamel lamellae are thin, leaflike faults between the enamel rod groups that extend from the enamel surface toward the DEJ, sometimes extending into dentin (see Fig. 1.10). They contain mostly organic material and may predispose the tooth to the entry of bacteria and subsequent development of dental caries. Enamel permeability decreases with age because of changes in the enamel matrix, a decrease referred to as *enamel maturation*.

Enamel is soluble when exposed to acidic conditions, but the dissolution is not uniform. Solubility of enamel increases from the enamel surface to the DEJ. When fluoride ions are present during enamel formation or are topically applied to the enamel surface, the solubility of surface enamel is decreased. Fluoride



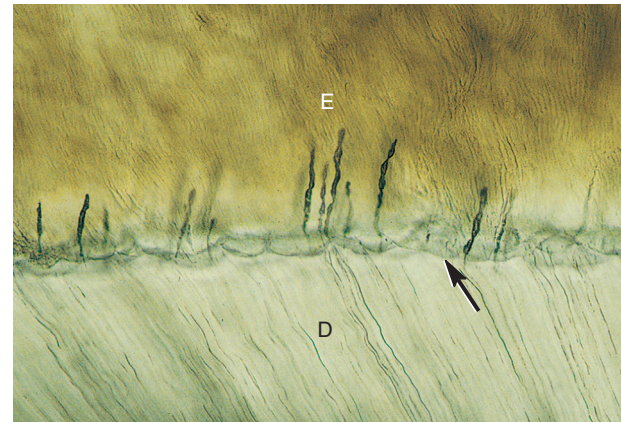
• **Fig. 1.9** Electron micrograph of mature, hexagon-shaped enamel crystallites. (From Nanci A: *Ten Cate's oral histology: development, structure, and function*, ed 7, St Louis, 2008, Mosby.)



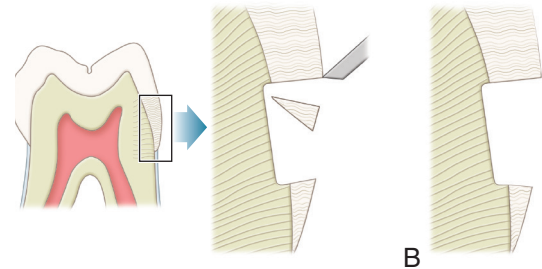
• **Fig. 1.10** Microscopic view through lamella that goes from enamel surface into dentin. Note the enamel tufts (arrow). (From Fehrenbach MJ, Popowics T: *Illustrated dental embryology, histology, and anatomy*, ed 4, St. Louis, 2016, Saunders. Courtesy James McIntosh, PhD, Assistant Professor Emeritus, Department of Biomedical Sciences, Baylor College of Dentistry, Dallas, TX.)

concentration decreases toward the DEJ. Fluoride is able to affect the chemical and physical properties of the apatite mineral and influence the hardness, chemical reactivity, and stability of enamel, while preserving the apatite structures. Trace amounts of fluoride stabilize enamel by lowering acid solubility, decreasing the rate of demineralization, and enhancing the rate of remineralization.

Enamel is the hardest substance of the human body. Hardness may vary over the external tooth surface according to the location; also, it decreases inward, with hardness lowest at the DEJ. The density of enamel also decreases from the surface to the DEJ. Enamel is a rigid structure that is both strong and brittle (high

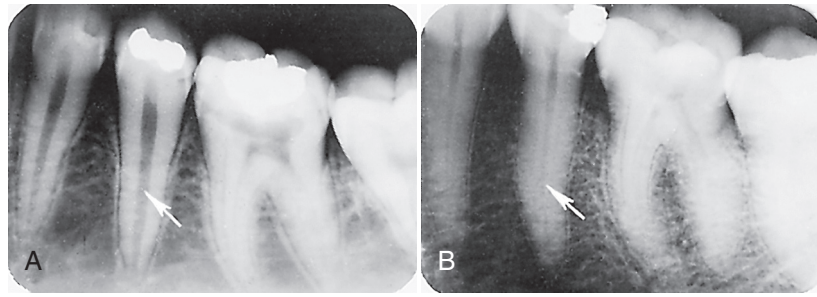


• **Fig. 1.11** Microscopic view of scalloped dentoenamel junction (DEJ; arrow). E, Enamel; D, dentin. (From Fehrenbach MJ, Popowics T: *Illustrated dental embryology, histology, and anatomy*, ed 4, St. Louis, 2016, Saunders. Courtesy James McIntosh, PhD, Assistant Professor Emeritus, Department of Biomedical Sciences, Baylor College of Dentistry, Dallas, TX.)



• **Fig. 1.12** A, Enamel rods unsupported by dentin base are fractured away readily by pressure from hand instrument. B, Cervical preparation showing enamel rods supported by dentin base.

elastic modulus, high compressive strength, and low tensile strength). The ability of the enamel to withstand masticatory forces depends on a stable attachment to the dentin by means of the DEJ. Dentin is a more flexible substance that is strong and resilient (low elastic modulus, high compressive strength, and high tensile strength), which essentially increases the fracture toughness of the more superficial enamel. The junction of enamel and dentin (DEJ) is scalloped or wavy in outline, with the crest of the waves penetrating toward enamel (Fig. 1.11). The rounded projections of enamel fit into the shallow depressions of dentin. This interdigitation may contribute to the durable connection of enamel to dentin. The DEJ is approximately 2 μm wide and is comprised of a mineralized complex of interwoven dentin and enamel matrix proteins. In addition to the physical, scalloped relationship between the enamel and dentin, an interphase matrix layer (made primarily of a fibrillary collagen network) extends 100 to 400 μm from the DEJ into the enamel. This matrix-modified interphase layer is considered to provide fracture propagation limiting properties to the interface between the enamel and the DEJ and thus overall structural stability of the enamel attachment to dentin.¹ Enamel rods that lack a dentin base because of caries or improper preparation design are easily fractured away from neighboring rods. For optimal strength in tooth preparation, all enamel rods should be supported by dentin (Fig. 1.12).



• **Fig. 1.13** Pulp cavity size. A, Premolar radiograph of young person. B, Premolar radiograph of older person. Note the difference in the size of the pulp cavity (arrows).

Pulp–Dentin Complex

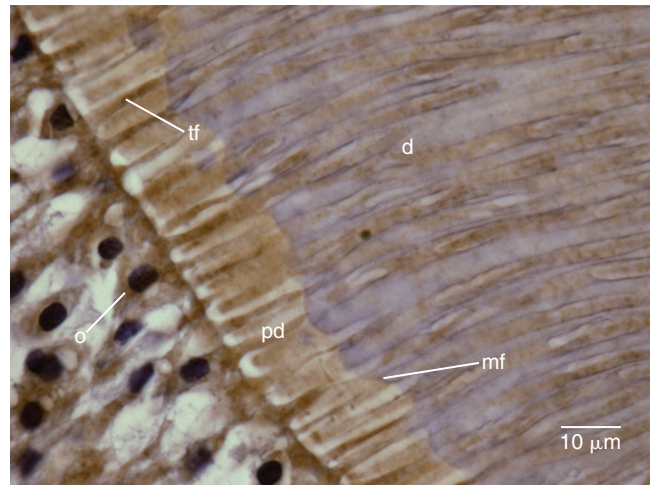
Pulp and dentin tissues are specialized connective tissues of mesodermal origin, formed from the dental papilla of the tooth bud. Many investigators consider these two tissues as a single tissue, which forms the pulp–dentin complex, with mineralized dentin constituting the mature end product of cell differentiation and maturation.

Dental pulp occupies the pulp cavity in the tooth and is a unique, specialized organ of the human body that serves four functions: (1) formative (developmental), (2) nutritive, (3) sensory (protective), and (4) defensive/repairative. The formative function is the production of primary and secondary dentin by odontoblasts. The nutritive function supplies mineral ions, proteins, and water to dentin through the blood supply to odontoblasts and their processes. The sensory function is provided by nerve fibers within the pulp that mediate the sensation of pain. Dentin nervous nociceptors are unique because various stimuli elicit only pain as a response. The pulp usually does not differentiate between heat, touch, pressure, or chemicals. Motor nerve fibers initiate reflexes in the muscles of the blood vessel walls for the control of circulation in the pulp. The defensive/repairative function is discussed in the subsequent section on *The Pulp–Dentin Complex: Response to Pathologic Challenge*.

The pulp is circumscribed by dentin and is lined peripherally by a cellular layer of odontoblasts adjacent to dentin. Anatomically, the pulp is divided into (1) coronal pulp located in the pulp chamber in the crown portion of the tooth, including the pulp horns that are located beneath the incisal ridges and cusp tips, and (2) radicular pulp located in the pulp canals in the root portion of the tooth. The radicular pulp is continuous with the periapical tissues through the apical foramen or foramina of the root. Accessory canals may extend from the pulp canals laterally through the root dentin to periodontal tissue. The shape of each pulp conforms generally to the shape of each tooth (see Fig. 1.3).

The pulp contains nerves, arterioles, venules, capillaries, lymph channels, connective tissue cells, intercellular substance, odontoblasts, fibroblasts, macrophages, collagen, and fine fibers.² The pulp is circumscribed peripherally by a specialized odontogenic area composed of the odontoblasts, the cell-free zone, and the cell-rich zone.

Knowledge of the contour and size of the pulp cavity is essential during tooth preparation. In general, the pulp cavity is a miniature contour of the external surface of the tooth. Pulp cavity size varies with tooth size in the same person and among individuals. With advancing age, the pulp cavity usually decreases in size. Radiographs are an invaluable aid in determining the size of the pulp cavity and any existing pathologic condition (Fig. 1.13). A primary



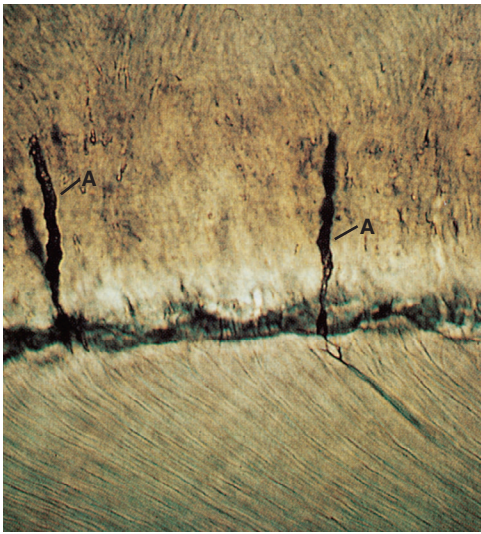
• **Fig. 1.14** Odontoblasts (*o*) have cell processes (Tomes fibers [*tf*]) that extend through the predentin (*pd*) into dentin (*d*). *mf*, Mineralization front.

objective during operative procedures must be the preservation of the health of the pulp.

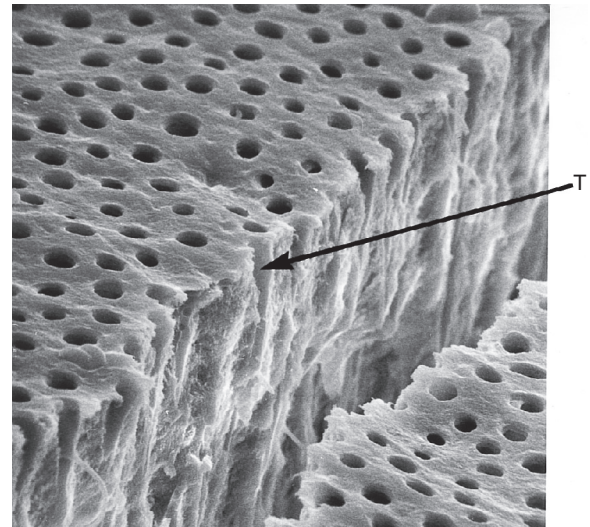
Dentin formation, *dentinogenesis*, is accomplished by cells called *odontoblasts*. Odontoblasts are considered part of pulp and dentin tissues because their cell bodies are in the pulp cavity, but their long, slender cytoplasmic cell processes (Tomes fibers) extend well (100–200 μm) into the tubules in the mineralized dentin (Fig. 1.14).

Because of these odontoblastic cell processes, dentin is considered a living tissue, with the capability of reacting to physiologic and pathologic stimuli. Odontoblastic processes occasionally cross the DEJ into enamel; these are termed *enamel spindles* when their ends are thickened (Fig. 1.15). Enamel spindles may serve as pain receptors, explaining the sensitivity experienced by some patients during tooth preparation that is limited to enamel only.

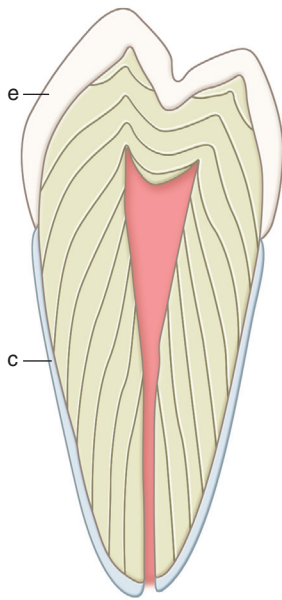
Dentin forms the largest portion of the tooth structure, extending almost the full length of the tooth. Externally, dentin is covered by enamel on the anatomic crown and cementum on the anatomic root. Internally, dentin forms the walls of the pulp cavity (pulp chamber and pulp canals) (Fig. 1.16). Dentin formation begins immediately before enamel formation. Odontoblasts generate an extracellular collagen matrix as they begin to move away from adjacent ameloblasts. Mineralization of the collagen matrix, facilitated by modification of the collagen matrix by various noncollagenous proteins, gradually follows its secretion. The most recently formed layer of dentin is always on the pulpal surface.




• **Fig. 1.15** Longitudinal section of enamel. Odontoblastic processes extend into enamel as enamel spindles (A). (From Berkovitz BKB, Holland GR, Moxham BJ: *Oral anatomy, histology and embryology*, ed 4, Edinburgh, 2009, Mosby. Courtesy of Dr. R. Sprinz.)



• **Fig. 1.17** Ground dental surface, acid-etched with 37% phosphoric acid. The artificial crack shows part of the dentinal tubules (T). The tubule apertures are opened and widened by acid application. (From Brännström M: *Dentin and pulp in restorative dentistry*, London, 1982, Wolfe Medical.)



• **Fig. 1.16** Pattern of formation of primary dentin. This figure also shows enamel (e) covering the anatomic crown of the tooth and cementum (c) covering the anatomic root.



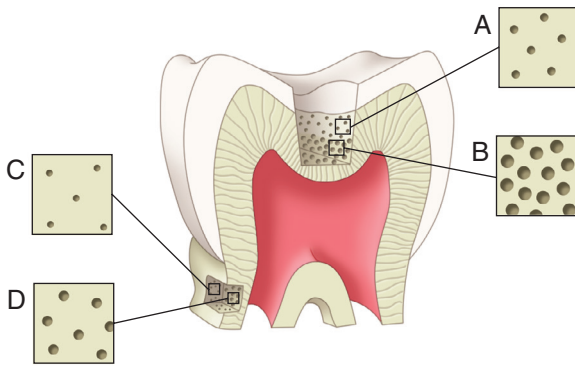
• **Fig. 1.18** Dentinal tubules in cross section, 1.2 mm from pulp. Peritubular dentin (P) is more mineralized than intertubular dentin (I). (From Brännström M: *Dentin and pulp in restorative dentistry*, London, 1982, Wolfe Medical.)

This unmineralized zone of dentin is immediately next to the cell bodies of odontoblasts and is called *predentin* (see Fig. 1.14). Dentin formation begins at areas subjacent to the cusp tip or incisal ridge and gradually spreads, at the rate of $\sim 4 \mu\text{m}/\text{day}$, to the apex of the root (see Fig. 1.16). In contrast to enamel formation, dentin formation continues after tooth eruption and throughout the life of the pulp. The dentin forming the initial shape of the tooth is called *primary dentin* and is usually completed 3 years after tooth eruption (in the case of permanent teeth).

The dentinal tubules are small canals that remain from the process of dentinogenesis and extend through the entire width of dentin, from the pulp to the DEJ (Figs. 1.17 and 1.18). Each tubule contains the cytoplasmic cell process (Tomes fiber) of an

odontoblast and is lined with a layer of peritubular dentin, which is much more mineralized than the surrounding intertubular dentin (see Fig. 1.18).

The surface area of dentin is much larger at the DEJ and dentinocemental junction than it is on the pulp cavity side. Because odontoblasts form dentin while progressing inward toward the pulp, the tubules are forced closer together. The number of tubules increases from 15,000 to 20,000/ mm^2 at the DEJ to 45,000 to 65,000/ mm^2 at the pulp.³ The lumen of the tubules also varies from the DEJ to the pulp surface. In coronal dentin, the average diameter of tubules at the DEJ is 0.5 to 0.9 μm , but this increases to 2 to 3 μm near the pulp (Fig. 1.19).



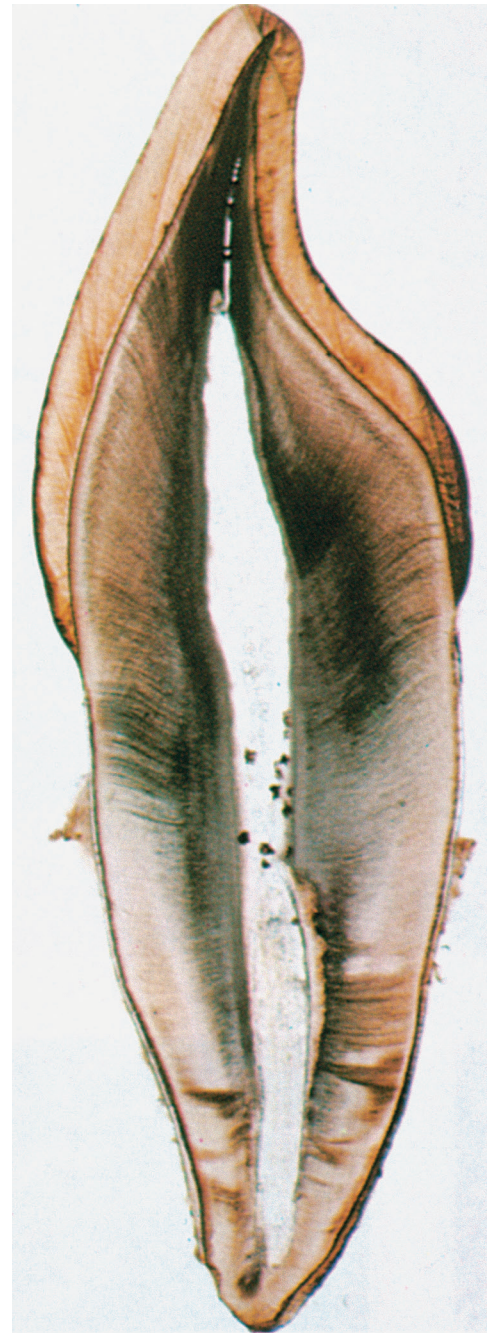• **Fig. 1.19** Tubules in superficial dentin close to the dentoenamel junction (DEJ) (A) are smaller and more sparsely distributed compared with deep dentin (B). The tubules in superficial root dentin (C) and deep root dentin (D) are smaller and less numerous than those in comparable depths of coronal dentin.

The course of the dentinal tubules is a slight S-curve in the tooth crown, but the tubules are straighter in the incisal ridges, cusps, and root areas (Fig. 1.20). Tubules are generally oriented perpendicular to the DEJ. Along the tubule walls are small lateral openings called *canaliculi* or lateral canals. The lateral canals are formed as a result of the presence of secondary (lateral) branches of adjacent odontoblastic processes during dentinogenesis. Near the DEJ, the tubules are divided into several branches, forming an intercommunicating and anastomosing network (Fig. 1.21).

After the primary dentin is formed, dentin deposition continues at a reduced rate ($\sim 0.4 \mu\text{m}/\text{day}$) even without obvious external stimuli, although the rate and amount of this physiologic secondary dentin vary considerably among individuals. In secondary dentin, the tubules take a slightly different directional pattern in contrast to the primary dentin (Fig. 1.22). The secondary dentin forms on all internal aspects of the pulp cavity, but in the pulp chamber, in multirooted teeth, it tends to be thicker on the roof and floor than on the side walls.⁴

The walls of the dentinal tubules (peritubular dentin) in the primary dentin gradually thicken, through ongoing mineral deposition, with age. The dentin therefore becomes harder, denser, and, because tubular fluid flow becomes more restricted as the lumen spaces become smaller, less sensitive. The increased amount of mineral in the primary dentin is defined as *dentin sclerosis*. Dentin sclerosis resulting from aging is called *physiologic dentin sclerosis*.

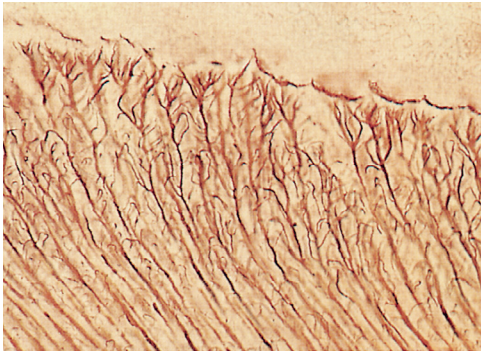
Human dentin is composed of approximately 50% inorganic material and 30% organic material by volume. The organic material is approximately 90% type I collagen and 10% noncollagenous proteins. Dentin is less mineralized than enamel but more mineralized than cementum or bone. The mineral content of dentin increases with age. The mineral phase is composed primarily of hydroxyapatite crystallites, which are arranged in a less systematic manner than are enamel crystallites. Dentinal crystallites are smaller than enamel crystallites, having a length of 20 to 100 nm and a width of about 3 nm, which is similar to the size seen in bone and cementum.⁴ Dentin is significantly softer than enamel but harder than bone or cementum. The hardness of dentin averages one fifth that of enamel, and its hardness near the DEJ is about three times greater than near the pulp. Although dentin is a hard, mineralized tissue, it is flexible, with a modulus of elasticity of approximately 18 gigapascals (GPa).⁵ This flexibility helps support the more brittle, less resilient enamel. Dentin is not as prone to fracture as is the enamel rod structure. Often small “craze lines”



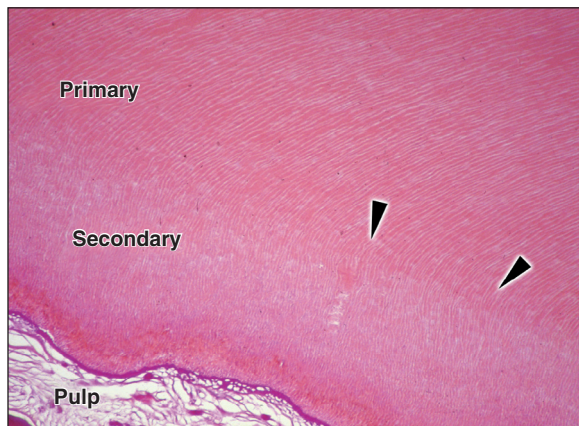
• **Fig. 1.20** Ground section of human incisor. Course of dentinal tubules is in a slight S-curve in the crown, but straight at the incisal tip and in the root. (From Young B, Lowe JS, Stevens A, Heath JW: *Wheater's functional histology: a text and colour atlas*, ed 5, Edinburgh, 2006, Churchill Livingstone.)

are seen in enamel, indicating minute fractures of that structure. The craze lines usually are not clinically significant unless associated with cracks in the underlying dentin. The ultimate tensile strength of dentin is approximately 98 megapascals (MPa), whereas the ultimate tensile strength of enamel is approximately 10 MPa. The compressive strength of dentin and enamel are approximately 297 and 384 MPa, respectively.⁵

During tooth preparation, dentin usually is distinguished from enamel by (1) color and opacity, (2) reflectance, (3) hardness, and (4) sound. Dentin is normally yellow-white and slightly darker



• **Fig. 1.21** Ground section showing dentinal tubules and their lateral branching close to the dentoenamel junction (DEJ). (From Berkovitz BKB, Holland GR, Moxham BJ: *Oral anatomy, histology, and embryology*, ed 4, Edinburgh, 2010, Mosby.)

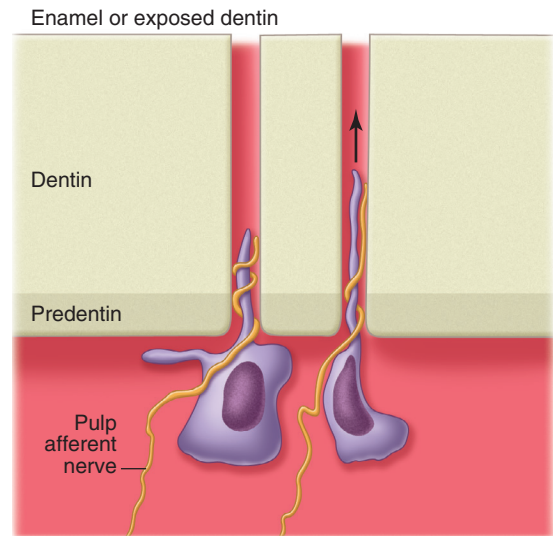


• **Fig. 1.22** Ground section of dentin with pulp surface at right. Dentinal tubules curve sharply as they move from primary to secondary dentin. Dentinal tubules are more irregular in shape in secondary dentin. (From Nanci A: *Ten Cate's oral histology: development, structure, and function*, ed 8, St. Louis, 2013, Mosby.)

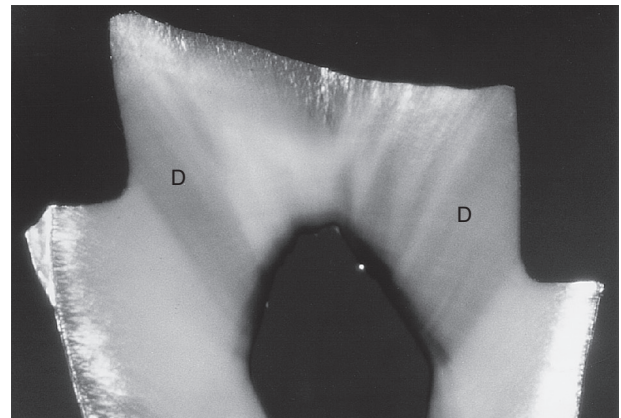
than enamel. In older patients, dentin is darker, and it can become brown or black when it has been exposed to oral fluids, old restorative materials, or slowly advancing caries. Dentin surfaces are more opaque and dull, being less reflective to light than similar enamel surfaces, which appear shiny. Dentin is softer than enamel and provides greater yield to the pressure of a sharp explorer tine, which tends to catch and hold in dentin.

Dentin sensitivity is perceived whenever nociceptor afferent nerve endings, in close proximity to odontoblastic processes within the dentinal tubules, are depolarized. The nerve transduction is most often interpreted by the central nervous system as pain. Physical, thermal, chemical, bacterial, and traumatic stimuli are remote from the nerve fibers and are detected through the fluid-filled dentinal tubules, although the precise mechanism of detection has not been conclusively established. The most accepted theory of stimulus detection is the *hydrodynamic theory*, which suggests that stimulus-initiated rapid tubular fluid movement within the dentinal tubules accounts for nerve depolarization.⁶ Operative procedures that involve cutting, drying, pressure changes, osmotic shifts, or changes in temperature result in rapid tubular fluid movement, which is perceived as pain (Fig. 1.23).

Dentinal tubules are filled with dentinal fluid, a transudate of plasma that contains all components necessary for mineralization

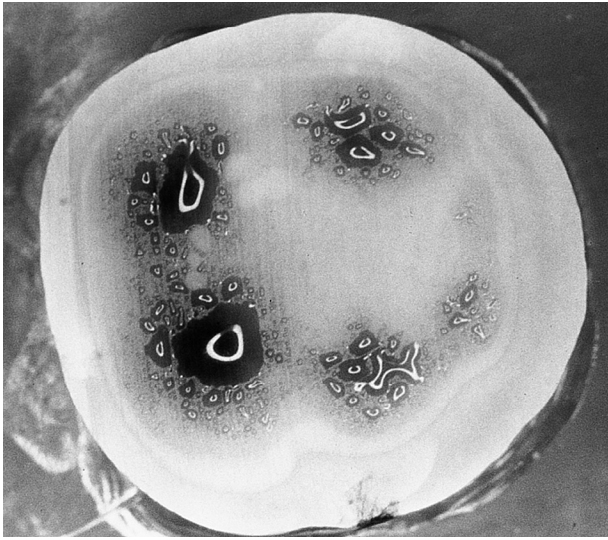


• **Fig. 1.23** Stimuli that induce rapid fluid movements in dentinal tubules distort odontoblasts and afferent nerves (arrow), leading to a sensation of pain. Many operative procedures such as cutting or air-drying induce rapid fluid movement.



• **Fig. 1.24** Ground section of MOD (mesio-occluso-distal) tooth preparation of a third molar. Dark blue dye was placed in the pulp chamber under pressure after tooth preparation. Dark areas of dye penetration (D) show that the dentinal tubules of axial walls are much more permeable than those of the pulpal floor of preparation.

to occur. These components include water, matrix proteins, matrix-modifying proteins, and mineral ions. The vital dental pulp has a slight positive pressure that results in continual dentinal fluid flow toward the external surface of the tooth. Enamel and cementum, though semipermeable, provide an effective layer serving to protect the underlying dentin and limit tubular fluid flow. When enamel or cementum is removed during tooth preparation, the protective layer is lost, allowing increased tubular fluid movement toward the cut surface. Permeability studies of dentin indicate that tubules are functionally much smaller than would be indicated by their measured microscopic dimensions as a result of numerous constrictions along their paths (see Fig. 1.18).⁷ Dentin permeability is not uniform throughout the tooth. Coronal dentin is much more permeable than root dentin. There also are differences within coronal dentin (Fig. 1.24).⁸ Dentin permeability primarily depends on the remaining dentin thickness (i.e., length of the tubules) and the diameter of the tubules. Because the tubules are shorter, more



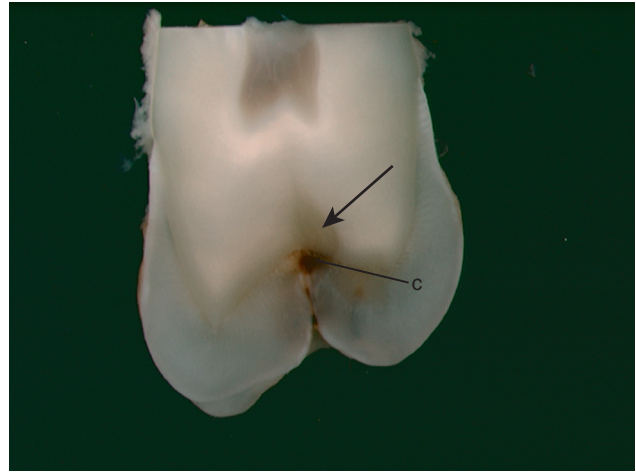• **Fig. 1.25** Horizontal section in the occlusal third of a molar crown. Dark blue dye was placed in the pulp chamber under pressure. Deep dentin areas (over pulp horns) are much more permeable than superficial dentin. (From Pashley DH, Andringa HJ, Derkson GD, Derkson ME, Kalathoor SR: Regional variability in the permeability of human dentin, *Arch Oral Biol* 32:519–523, 1987, with permission from Pergamon, Oxford, UK.)

numerous, and larger in diameter closer to the pulp, deep dentin is a less effective pulpal barrier compared with superficial dentin (Fig. 1.25).

The Pulp–Dentin Complex: Response to Pathologic Challenge

The pulp–dentin complex responds to tooth pathology through pulpal immune–inflammation defense systems and dentin repair/formation. The defensive and reparative functions of the pulp are mediated by an extremely complex host–defense response to bacterial, chemical, mechanical, and/or thermal irritation.⁹ Primary odontoblasts are the first to respond to lesion formation and communicate with the deeper pulp tissue (via cytokines and chemokines) such that an adaptive and innate inflammatory reaction begins. Mild to moderate injury normally causes a reversible inflammatory response in the pulp, referred to as *reversible pulpitis*, which resolves when the pathology is removed. Moderate to severe injury (e.g., deep caries) may cause the degeneration of the affected odontoblastic processes and death of the corresponding primary odontoblasts. Toxic bacterial products, molecules released from the demineralized dentin matrix, and/or high concentrations of inflammatory response mediators may signal death of the primary odontoblasts. In cases of severe injury, an irreversible inflammatory response of the pulp (*irreversible pulpitis*) will ultimately result in capillary dilation, local edema, stagnation of blood flow, anoxia, and ultimately pulpal necrosis (see Chapter 2).

Very early host–defense processes in primary dentin seek to block the advancement of a caries lesion by means of the precipitation of mineral in the lumens of the dentinal tubules of the affected area. The physical occlusion of the tubular lumens increases the ability of light to pass through this localized region (i.e., increases its transparency). This dentin is referred to as *transparent dentin* (Fig. 1.26).¹⁰ Dentin in this area is not as hard as normal primary dentin because of mineral loss in the intertubular dentin (see Chapter 2). Successful host–defense repair processes result in the



• **Fig. 1.26** Transparent dentin (arrow) beneath a caries lesion (c).

remineralization of the intertubular dentin, in addition to the mineral occlusion of the dentinal tubules, such that the final hardness of the dentin in this affected area is greater than normal primary dentin. The increased overall mineralization of this caries-affected primary dentin is referred to as *reactive dentin sclerosis*.

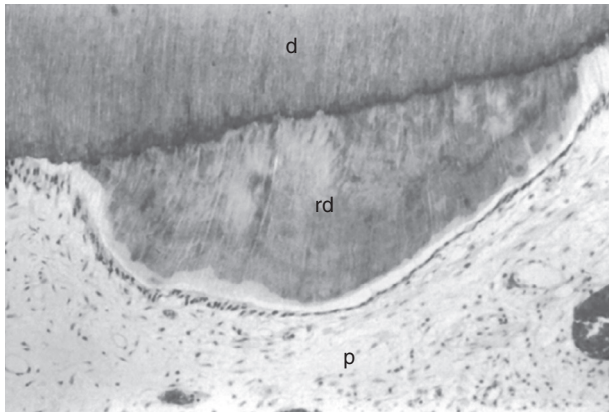
Deep dentin formation processes occur simultaneously with the pulpal inflammatory response and result in the generation of *tertiary dentin* at the pulp–dentin interface. The net effect of these processes is to increase the thickness/effectiveness of the dentin as a protective barrier for the pulp tissue. Two types of tertiary dentin form in response to lesion formation. In the case of mild injury (e.g., a shallow caries lesion), primary odontoblasts initiate increased formation of dentin along the internal aspect of the dentin beneath the affected area through secretion of *reactionary tertiary dentin* (or “reactionary dentin”). Reactionary dentin is tubular in nature and is continuous with primary and secondary dentin.

More severe injury (e.g., a deep caries lesion) causes the death of the primary odontoblasts. When therapeutic steps successfully resolve the injury, replacement cells (variously referred to as *secondary odontoblasts*, *odontoblast-like cells*, or *odontoblastoid cells*) differentiate from pulpal mesenchymal cells. The secondary odontoblasts subsequently generate *reparative tertiary dentin* (or “reparative dentin”) as a part of the ongoing host defense. Reparative dentin usually appears as a localized dentin deposit on the wall of the pulp cavity immediately subjacent to the area on the tooth that had received the injury (Fig. 1.27). Reparative dentin is generally atubular and therefore structurally different from the primary and secondary dentin.

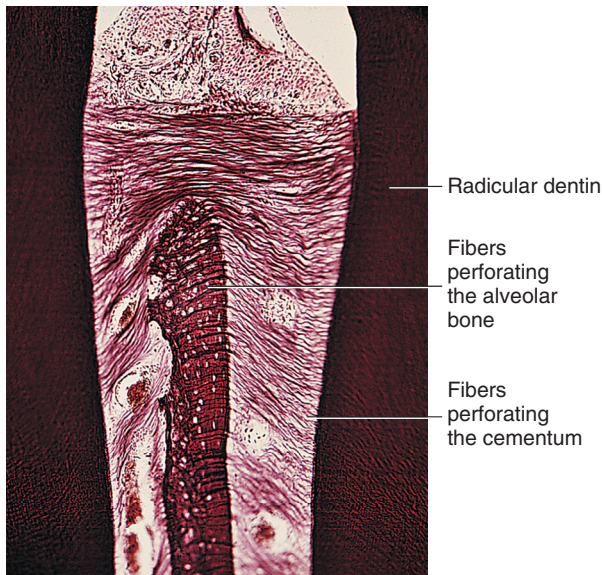
Cementum

Cementum is a thin layer of hard dental tissue covering the anatomic roots of teeth. It is formed by cells known as *cementoblasts*, which develop from undifferentiated mesenchymal cells in the connective tissue of the dental follicle. Cementum is slightly softer than dentin and consists of about 45% to 50% inorganic material (hydroxyapatite) by weight and 50% to 55% organic matter and water by weight. The organic portion is composed primarily of collagen and protein polysaccharides. *Sharpey fibers* are portions of the principal collagen fibers of the periodontal ligament embedded in cementum and alveolar bone to attach the tooth to the alveolus (Fig. 1.28). Cementum is avascular.

Cementum is yellow and slightly lighter in color than dentin. It is formed continuously throughout life because, as the superficial



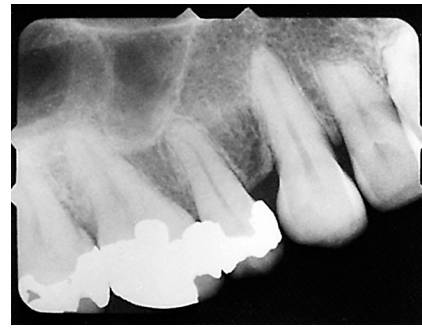• **Fig. 1.27** Reparative dentin in response to a caries lesion. *d*, Dentin; *rd*, reparative dentin; *p*, pulp. (From Trowbridge HO: Pulp biology: Progress during the past 25 years, *Aust Endo J* 29(1):5–12, 2003.)



• **Fig. 1.28** Principal fibers of periodontal ligament continue into surface layer of cementum as Sharpey fibers. (Modified from Chiego DJ Jr: *Essentials of oral histology and embryology: A clinical approach*, ed 4, St Louis, 2014, Mosby.)

layer of cementum ages, a new layer of cementum is deposited to keep the attachment intact. *Acellular cementum* (i.e., there are no cementoblasts) is predominately associated with the coronal half of the root. *Cellular cementum* is more frequently associated with the apical half of the root. Cementum on the root end surrounds the apical foramen and may extend slightly onto the inner wall of the pulp canal. Cementum thickness may increase on the root end to compensate for attritional wear of the occlusal or incisal surface and passive eruption of the tooth.

The cementodentinal junction is relatively smooth in the permanent tooth. The attachment of cementum to dentin, although not completely understood, is very durable. Cementum joins enamel to form the CEJ. In about 10% of teeth, enamel and cementum do not meet, and this can result in a sensitive area as the openings of the dentinal tubules are not covered. Abrasion, erosion, caries, scaling, and restoration finishing/polishing procedures may denude dentin of its cementum covering. This may lead to sensitivity to various stimuli (e.g., heat, cold, sweet substances, sour substances).



• **Fig. 1.29** Radiograph showing root resorption on lateral incisor after orthodontic tooth movement.

Cementum is capable of repairing itself to a limited degree and is not resorbed under normal conditions. Some resorption of the apical portion of the root cementum and dentin may occur, however, if orthodontic pressures are excessive and movement is too fast (Fig. 1.29).

Physiology of Tooth Form

Function

Teeth serve four main functions: (1) mastication, (2) esthetics, (3) speech, and (4) protection of supporting tissues. Normal tooth form and proper alignment ensure efficiency in the incising and reduction of food. The various tooth classes—incisors, canines, premolars, and molars—perform specific functions in the masticatory process and in the coordination of the various muscles of mastication. The form and alignment of anterior teeth contribute to the esthetics of personal physical appearance. The form and alignment of anterior and posterior teeth assist in the articulation of certain sounds so as to effect proper speech. Finally, the form and alignment of teeth assist in the development and protection of supporting gingival tissue and alveolar bone.

Contours

Facial and lingual surfaces possess a degree of convexity that affords protection and stimulation of supporting tissues during mastication. The convexity generally is located at the cervical third of the crown on the facial surfaces of all teeth and the lingual surfaces of incisors and canines. Lingual surfaces of posterior teeth usually have their height of contour in the middle third of the crown. Normal tooth contours act in deflecting food only to the extent that the passing food stimulates (by gentle massage) and does not irritate (abrade) supporting soft tissues. If these curvatures are too great, tissues usually receive inadequate stimulation by the passage of food. Too little contour may result in trauma to the attachment apparatus. Normal tooth contours must be recreated in the performance of operative dental procedures. Improper location and degree of facial or lingual convexities may result in iatrogenic injury, as illustrated in Fig. 1.30, in which the proper facial contour is disregarded in the design of the cervical area of a mandibular molar restoration. Overcontouring is the worst offender, usually resulting in increased plaque retention that leads to a chronic inflammatory state of the gingiva.

Proper form of the proximal surfaces of teeth is just as important to the maintenance of periodontal tissue health as is the proper form of facial and lingual surfaces. The proximal height of contour serves to provide (1) contacts with the proximal surfaces of adjacent teeth, thus preventing food impaction, and (2) adequate embrasure

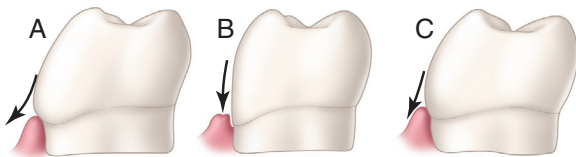
space (immediately apical to the contacts) for gingival tissue, supporting bone, blood vessels, and nerves that serve the supporting structures (Fig. 1.31).

Proximal Contact Area

When teeth initially erupt to make proximal contact with previously erupted teeth, a contact *point* is present. The contact point increases in size to become a proximal contact *area* as the two adjacent tooth surfaces abrade each other during physiologic tooth movement (Figs. 1.32 and 1.33).

The physiologic significance of properly formed and located proximal contacts cannot be overemphasized; they promote normal healthy interdental papillae filling the interproximal spaces. Improper contacts may result in food impaction between teeth, potentially increasing the risk of periodontal disease, caries, and tooth movement. In addition, retention of food is objectionable because of its physical presence and the halitosis that results from food decomposition. Proximal contacts and interdigitation of maxillary and mandibular teeth, through occlusal contact areas, stabilize and maintain the integrity of the dental arches.

The proximal contact area is located in the incisal third of the approximating surfaces of maxillary and mandibular central incisors (see Fig. 1.33). It is positioned slightly facial to the center of the proximal surface faciolingually (see Fig. 1.32). Proceeding posteriorly



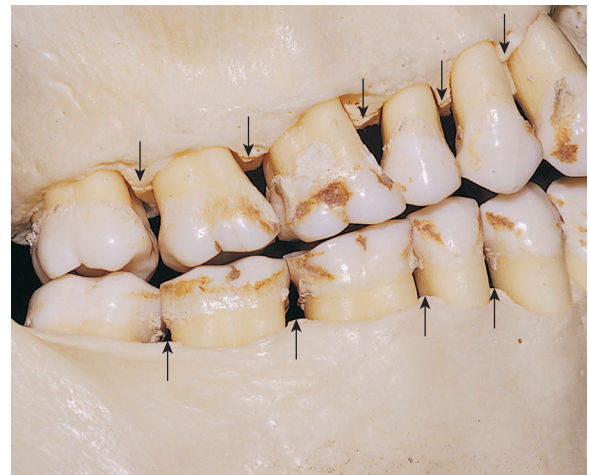• **Fig. 1.30** Contours. Arrows show pathways of food passing over facial surface of mandibular molar during mastication. A, Overcontour deflects food from gingiva and results in understimulation of supporting tissues. B, Undercontour of tooth may result in irritation of soft tissue. C, Correct contour permits adequate stimulation and protection of supporting tissue.

from the incisor region through all the remaining teeth, the contact area is located near the junction of the incisal (or occlusal) and middle thirds or in the middle third. Proximal contact areas typically are larger in the molar region, which helps prevent gingival food impaction during mastication. Adjacent surfaces near the proximal contacts (embrasures) usually have remarkable symmetry.

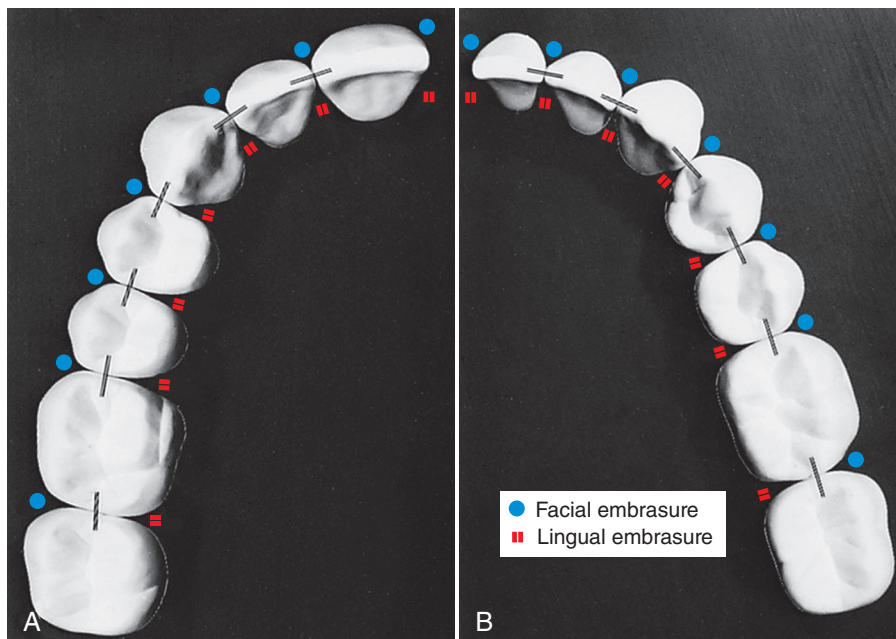
Embrasures

Embrasures are V-shaped spaces that originate at the proximal contact areas between adjacent teeth and are named for the direction toward which they radiate. These embrasures are (1) facial, (2) lingual, (3) incisal or occlusal, and (4) gingival (see Figs. 1.32 and 1.33).

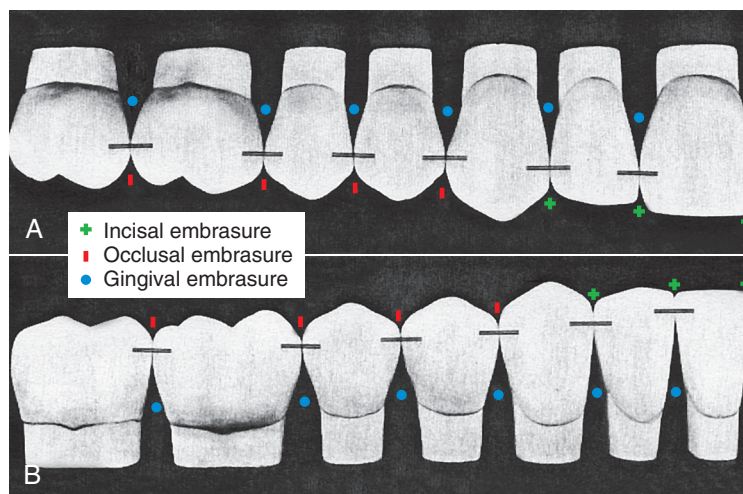
Initially, the interdental papilla fills the gingival embrasure. When the form and function of teeth are ideal and optimal oral



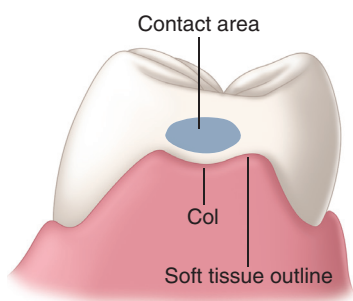
• **Fig. 1.31** Portion of the skull, showing triangular spaces beneath proximal contact areas. These spaces are occupied by soft tissue and bone for the support of teeth.



• **Fig. 1.32** Proximal contact areas. Black lines show positions of contact faciolingually. A, Maxillary teeth. B, Mandibular teeth. Facial and lingual embrasures are indicated.



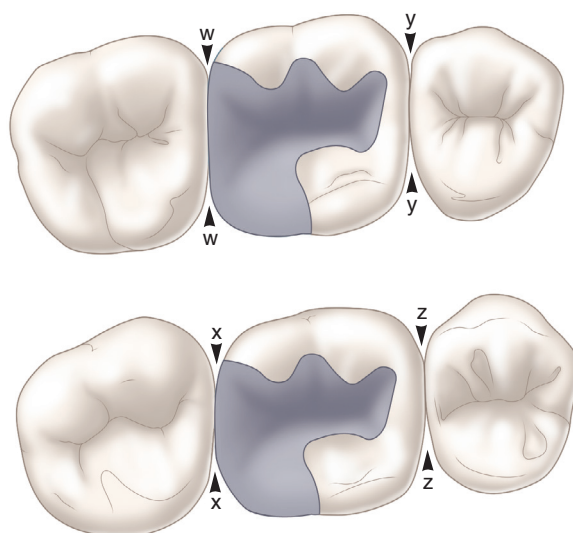
• **Fig. 1.33** Proximal contact areas. Black lines show positions of contact incisivally and occlusally. Incisal, occlusal, and gingival embrasures are indicated. A, Maxillary teeth. B, Mandibular teeth.



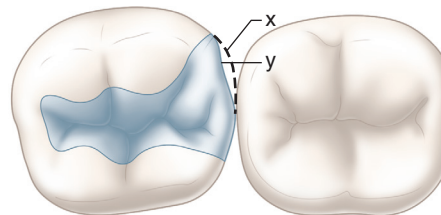
• **Fig. 1.34** Relationship of ideal interdental papilla to molar contact area.

health is maintained, the interdental papilla may continue in this position throughout life. When the gingival embrasure is filled by the papilla, trapping of food in this region is prevented. In a faciolingual vertical section, the papilla is seen to have a triangular shape between anterior teeth, whereas in posterior teeth, the papilla may be shaped like a mountain range, with facial and lingual peaks and the col (“valley”) lying beneath the contact area (Fig. 1.34). This col, a central faciolingual concave area beneath the contact, is more vulnerable to periodontal disease from incorrect contact and embrasure form because it is covered by nonkeratinized epithelium.

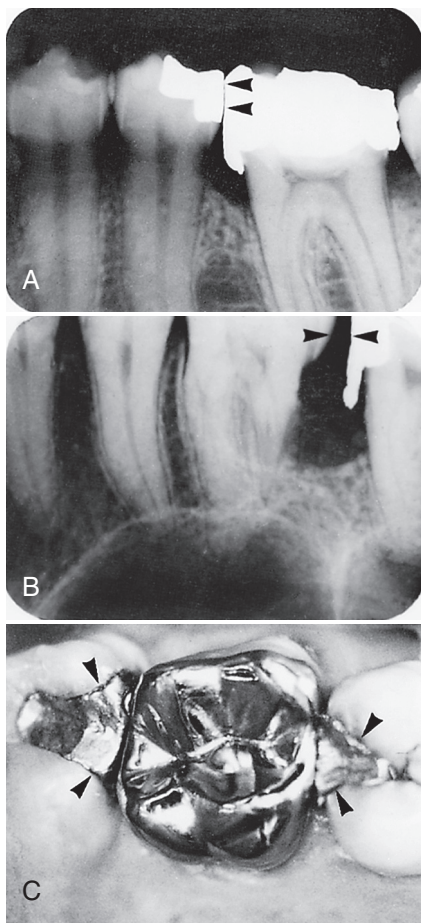
The correct relationships of embrasures, cusps to sulci, marginal ridges, and grooves of adjacent and opposing teeth provide for the escape of food from the occlusal surfaces during mastication. When an embrasure is decreased in size or absent, additional stress is created on teeth and the supporting structures during mastication. Embrasures that are too large provide little protection to the supporting structures as food is forced into the interproximal space by an opposing cusp (Fig. 1.35). A prime example is the failure to restore the distal cusp of a mandibular first molar when placing a restoration (Fig. 1.36). Lingual embrasures are usually larger than facial embrasures; and this allows more food to be displaced lingually because the tongue can return the food to the occlusal surface more easily than if the food is displaced facially into the buccal vestibule (see Fig. 1.32). The marginal ridges of adjacent posterior teeth should be be at the same height to have proper contact and embrasure forms. When this relationship is absent, it may



• **Fig. 1.35** Embrasure form. w, Improper embrasure form caused by overcontouring of restoration resulting in unhealthy gingiva from lack of stimulation. x, Good embrasure form. y, Frictional wear of contact area has resulted in decrease of embrasure dimension. z, When the embrasure form is good, supporting tissues receive adequate stimulation from foods during mastication.



• **Fig. 1.36** Embrasure form. x, Portion of tooth that offers protection to underlying supporting tissue during mastication. y, Restoration fails to establish adequate contour for good embrasure form.



• **Fig. 1.37** Poor anatomic restorative form. A, Radiograph of flat contact/amalgam gingival excess and resultant vertical osseous loss. B, Radiograph of restoration with amalgam gingival excess and absence of contact resulting in osseous loss, adjacent root caries. C, Poor embrasure form and restoration margins.

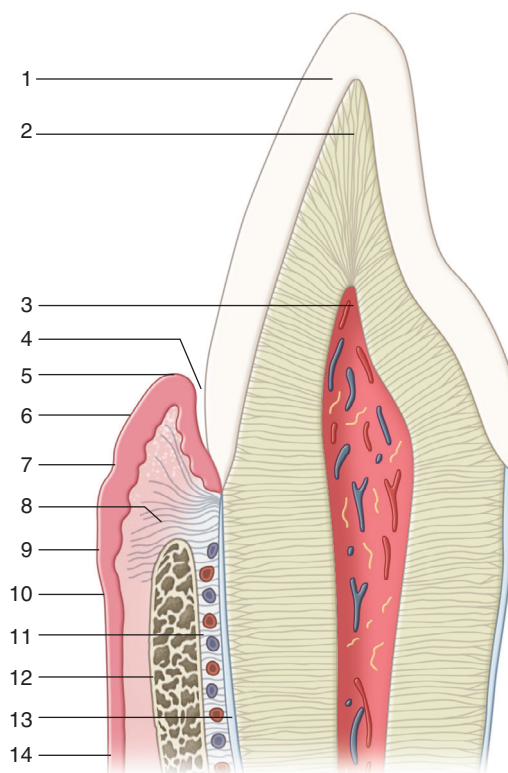
cause an increase in the problems associated with inadequate proximal contacts and faulty embrasure forms.

Preservation of the curvatures of opposing cusps and surfaces in function maintains masticatory efficiency throughout life (see Fig. 1.2). Correct anatomic form renders teeth more self-cleansing because of the smoothly rounded contours that are more exposed to the cleansing action of foods and fluids and the frictional movement of the tongue, lips, and cheeks. Failure to understand and adhere to correct anatomic form may contribute to the breakdown of the restored system (Fig. 1.37).

Maxilla and Mandible

The human maxilla is formed by two bones, the maxilla proper and the premaxilla. These two bones form the bulk of the upper jaw and the major portion of the hard palate and help form the floor of the orbit and the sides and base of the nasal cavity. They contain 10 maxillary primary teeth initially and later contain 16 maxillary permanent teeth in the alveolar process (see Figs. 1.1 and 1.3, label 7).

The mandible, or the lower jaw, is horseshoe shaped and relates to the skull on either side via the TMJs. The mandible is composed of a body of two horizontal portions joined at the midline symphysis mandibulae and the rami, the vertical parts. The coronoid process



• **Fig. 1.38** Vertical section of a maxillary incisor illustrating supporting structures: 1, enamel; 2, dentin; 3, pulp; 4, gingival sulcus; 5, free gingival margin; 6, free gingiva; 7, free gingival groove; 8, lamina propria of gingiva; 9, attached gingiva; 10, mucogingival junction; 11, periodontal ligament; 12, alveolar bone; 13, cementum; 14, alveolar mucosa.

and the condyle make up the superior border of each ramus. The mandible initially contains 10 mandibular primary teeth and later 16 mandibular permanent teeth in the alveolar process. Maxillary and mandibular bones comprise approximately 38% to 43% inorganic material and 34% organic material by volume. The inorganic material is hydroxyapatite, and the organic material is primarily type I collagen, which is surrounded by a ground substance of glycoproteins and proteoglycans.

Oral Mucosa

The oral mucosa is the mucous membrane that covers all oral structures except the clinical crowns of teeth. It is composed of two layers: (1) the stratified squamous epithelium and (2) the supporting connective tissue, called *lamina propria*. (See the lamina propria of the gingiva in Fig. 1.38, indicator 8.) The epithelium may be keratinized, parakeratinized, or nonkeratinized, depending on its location. The lamina propria varies in thickness and supports the epithelium. It may be attached to the periosteum of alveolar bone, or it may be interposed over the submucosa, which may vary in different regions of the mouth (e.g., the floor of the mouth, the soft palate). The submucosa, consisting of connective tissues varying in density and thickness, attaches the mucous membrane to the underlying bony structures. The submucosa contains glands, blood vessels, nerves, and adipose tissue.

Oral mucosa is classified into three major functional types: (1) masticatory mucosa, (2) lining or reflective mucosa, and (3) specialized mucosa. The masticatory mucosa comprises the free and attached gingiva (see Fig. 1.38, indicators 6 and 9) and the mucosa

of the hard palate. The epithelium of these tissues is keratinized, and the lamina propria is a dense, thick, firm connective tissue containing collagen fibers. The hard palate has a distinct submucosa except for a few narrow specific zones. The dense lamina propria of the attached gingiva is connected to the cementum and periosteum of the bony alveolar process (see Fig. 1.38, indicator 8).

The lining or reflective mucosa covers the inside of the lips, cheek, and vestibule, the lateral surfaces of the alveolar process (except the mucosa of the hard palate), the floor of the mouth, the soft palate, and the ventral surface of the tongue. The lining mucosa is a thin, movable tissue with a relatively thick, nonkeratinized epithelium and a thin lamina propria. The submucosa comprises mostly thin, loose connective tissue with muscle and collagenous and elastic fibers, with different areas varying from one another in their structures. The junction of the lining mucosa and the masticatory mucosa is the mucogingival junction, located at the apical border of the attached gingiva facially and lingually in the mandibular arch and facially in the maxillary arch (see Fig. 1.38, indicator 10). The specialized mucosa covers the dorsum of the tongue and the taste buds. The epithelium is nonkeratinized except for the covering of the dermal filiform papillae.

Periodontium

The periodontium consists of the oral hard and soft tissues that invest and support teeth. It may be divided into (1) the gingival unit, consisting of free and attached gingiva and the alveolar mucosa, and (2) the attachment apparatus, consisting of cementum, the periodontal ligament, and the alveolar process (see Fig. 1.38).

Gingival Unit

As mentioned, the free gingiva and the attached gingiva together form the masticatory mucosa. The free gingiva is the gingiva from the marginal crest to the level of the base of the gingival sulcus (see Fig. 1.38, indicators 4 and 6). The gingival sulcus is the space between the tooth and the free gingiva. The outer wall of the sulcus (inner wall of the free gingiva) is lined with a thin, nonkeratinized epithelium. The outer aspect of the free gingiva in each gingival embrasure is called *gingival* or *interdental papilla*. The free gingival groove is a shallow groove that runs parallel to the marginal crest of the free gingiva and usually indicates the level of the base of the gingival sulcus (see Fig. 1.38, indicator 7).

The attached gingiva, a dense connective tissue with keratinized, stratified, squamous epithelium, extends from the depth of the gingival sulcus to the mucogingival junction. A dense network of collagen fibers connects the attached gingiva firmly to cementum and the periosteum of the alveolar process (bone).

The alveolar mucosa is a thin, soft tissue that is loosely attached to the underlying alveolar bone (see Fig. 1.38, indicators 12 and 14). It is covered by a thin, nonkeratinized epithelial layer. The underlying submucosa contains loosely arranged collagen fibers, elastic tissue, fat, and muscle tissue. The alveolar mucosa is delineated from the attached gingiva by the mucogingival junction and continues apically to the vestibular fornix and the inside of the cheek.

Clinically, the level of the gingival attachment and gingival sulcus is an important factor in restorative dentistry. Soft tissue health must be maintained by teeth having the correct anatomic form and position to prevent recession of the gingiva and possible abrasion and erosion of the root surfaces. The margin of a tooth preparation should not be positioned subgingivally (at levels between the marginal crest of the free gingiva and the base of the sulcus)

unless dictated by caries, previous restoration, esthetics, or other preparation requirements.

Attachment Apparatus

The tooth root is attached to the alveolus (bony socket) by the periodontal ligament (see Fig. 1.38, indicator 11), which is a complex connective tissue containing numerous cells, blood vessels, nerves, and an extracellular substance consisting of fibers and ground substance. Most of the fibers are collagen, and the ground substance is composed of a variety of proteins and polysaccharides. The periodontal ligament serves the following functions: (1) attachment and support, (2) sensory, (3) nutritive, and (4) homeostatic. Bundles of collagen fibers, known as *principal fibers of the ligament*, serve to connect between cementum and alveolar bone so as to suspend and support the tooth. Coordination of masticatory muscle function is achieved, through an efficient proprioceptive mechanism, by the sensory nerves located in the periodontal ligament. Blood vessels supply the attachment apparatus with nutritive substances. Specialized cells of the ligament function to resorb and replace cementum, the periodontal ligament, and alveolar bone.

The alveolar process—a part of the maxilla and the mandible—forms, supports, and lines the sockets into which the roots of teeth fit. Anatomically, no distinct boundary exists between the body of the maxilla or the mandible and the alveolar process. The alveolar process comprises thin, compact bone with many small openings through which blood vessels, lymphatics, and nerves pass. The inner wall of the bony socket consists of the thin lamella of bone that surrounds the root of the tooth and is termed *alveolar bone proper*. The second part of the bone is called *supporting alveolar bone*, which surrounds and supports the alveolar bone proper. Supporting bone is composed of two parts: (1) the cortical plate, consisting of compact bone and forming the inner (lingual) and outer (facial) plates of the alveolar process, and (2) the spongy base that fills the area between the plates and the alveolar bone proper.

Occlusion

Occlusion literally means “closing”; in dentistry, the term means the contact of teeth in opposing dental arches when the jaws are closed (static occlusal relationships) and during various jaw movements (dynamic occlusal relationships). The size of the jaw and the arrangement of teeth within the jaw are subject to a wide range of variation. The locations of contacts between opposing teeth (occlusal contacts) vary as a result of differences in the sizes and shapes of teeth and jaws and the relative position of the jaws. A wide variety of occlusal schemes are found in healthy individuals. Consequently, definition of an ideal occlusal scheme is fraught with difficulty.¹¹ Repeated attempts have been made to describe an ideal occlusal scheme, but these descriptions are so restrictive that few individuals can be found to fit the criteria. Failing to find a single adequate definition of an ideal occlusal scheme has resulted in the conclusion that “in the final analysis, optimal function and the absence of disease is the principal characteristic of a good occlusion.”¹¹ The dental relationships described in this section conform to the concepts of normal, or usual, occlusal schemes and include common variations of tooth-and-jaw relationships. The masticatory system (muscles, TMJs, and teeth) is highly adaptable and usually able to successfully function over a wide range of differences in jaw size and tooth alignment. Despite this great adaptability, however, some patients are highly sensitive to changes in tooth contacts (which influence the masticatory muscles

and TMJs), which may be brought about by orthodontic and restorative dental procedures.

Occlusal contact patterns vary with the position of the mandible. Static occlusion is defined further by the use of reference positions that include fully closed, terminal hinge (TH) closure, retruded, protruded, and right and left lateral extremes. The number and location of occlusal contacts between opposing teeth have important effects on the amount and direction of muscle force applied during mastication and other parafunctional activities such as mandibular clenching, tooth grinding, or a combination of both (bruxism). In extreme cases, these forces damage the teeth and/or their supporting tissues. Forceful tooth contact occurs routinely near the limits or borders of mandibular movement, showing the relevance of these reference positions.¹²

Tooth contact during mandibular movement is termed *dynamic occlusal relationship*. Gliding or sliding contacts occur during mastication and other mandibular movements. Gliding contacts may be advantageous or disadvantageous, depending on the teeth involved, the position of the contacts, and the resultant masticatory muscle response. The design of the restored tooth surface will have important effects on the number and location of occlusal contacts, and both static and dynamic relationships must be taken into consideration. The following sections discuss common arrangements and variations of teeth and the masticatory system. Mastication and the contacting relationships of anterior and posterior teeth are described with reference to the potential restorative needs of teeth.

General Description

Tooth Alignment and Dental Arches

In Fig. 1.39A, the cusps have been drawn as blunt, rounded, or pointed projections of the crowns of teeth. Posterior teeth have one, two, or three cusps near the facial and lingual surfaces of each tooth. Cusps are separated by distinct developmental grooves and sometimes have additional supplemental grooves on cusp inclines. Facial cusps are separated from the lingual cusps by a deep groove, termed *central groove*. If a tooth has multiple facial cusps or multiple lingual cusps, the cusps are separated by facial or lingual developmental grooves. The depressions between the cusps are termed *fossae* (singular, *fossa*). Cusps in both arches are aligned in a smooth curve. Usually, the maxillary arch is larger than the mandibular arch, which results in maxillary cusps overlapping mandibular cusps when the arches are in maximal occlusal contact (see Fig. 1.39B). In Fig. 1.39A, two curved lines have been drawn over the teeth to aid in the visualization of the arch form. These curved lines identify the alignment of similarly functioning cusps or fossae. On the left side of the arches, an imaginary arc connecting the row of facial cusps in the mandibular arch have been drawn and labeled *facial occlusal line*. Above that, an imaginary line connecting the maxillary central fossae is labeled *central fossa occlusal line*. The mandibular facial occlusal line and the maxillary central fossa occlusal line coincide exactly when the mandibular arch is fully closed into the maxillary arch. On the right side of the dental arches, the maxillary lingual occlusal line and mandibular central fossa occlusal line have been drawn and labeled. These lines also coincide when the mandible is fully closed.

In Fig. 1.39B, the dental arches are fully interdigitated, with maxillary teeth overlapping mandibular teeth. The overlap of the maxillary cusps may be observed directly when the jaws are closed. *Maximum intercuspation (MI)* refers to the position of the mandible when teeth are brought into full interdigitation with the maximal number of teeth contacting. Synonyms for MI include *intercuspal*

contact, *maximum closure*, and *maximum habitual intercuspation (MHI)*.

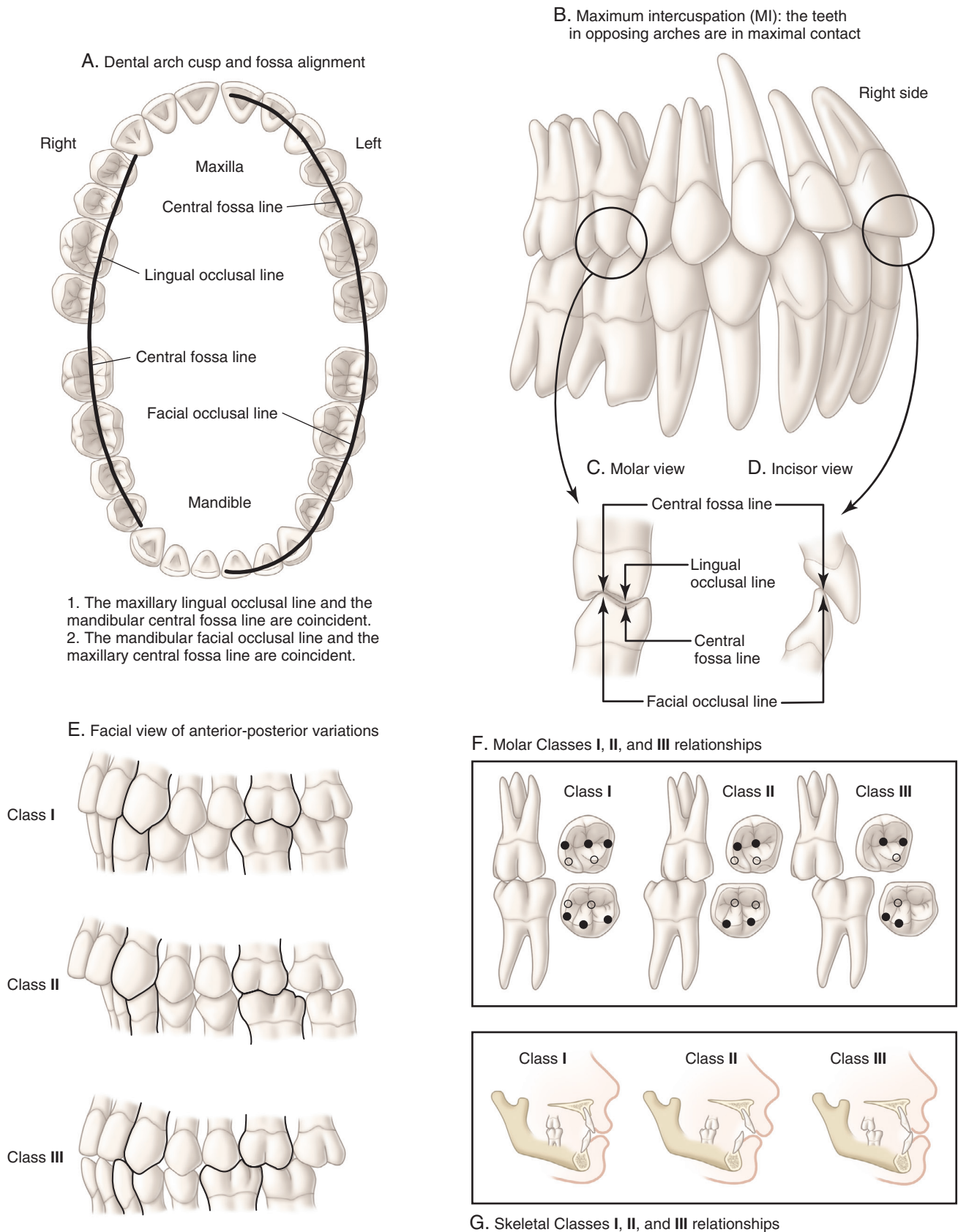
In Fig. 1.39C (proximal view), the mandibular facial occlusal line and the maxillary central fossa occlusal line coincide exactly. The maxillary lingual occlusal line and the mandibular central fossa occlusal line identified in Fig. 1.39A also are coincidental. The cusps that contact opposing teeth along the central fossa occlusal line are termed *functional cusps* (synonyms include supporting, holding, or stamp cusps); the cusps that overlap opposing teeth are termed *nonfunctional cusps* (synonyms include nonsupporting or nonholding cusps). The mandibular facial occlusal line identifies the mandibular functional cusps, whereas the maxillary facial cusps are nonfunctional cusps. These terms are usually applied only to posterior teeth to distinguish the functions of the two rows of cusps. In some circumstances, the functional role of the cusps may be reversed, as illustrated in Fig. 1.40C.2. Posterior teeth are well suited to crushing food because of the mutual cusp–fossa contacts (Fig. 1.41D).

In Fig. 1.39D, anterior teeth are seen to have a different relationship in MI, but they also show the characteristic maxillary overlap. Incisors are best suited to shearing food because of their overlap and the sliding contact on the lingual surface of maxillary teeth. In MI, mandibular incisors and canines contact the respective lingual surfaces of their maxillary opponents. The amount of horizontal (overjet) and vertical (overbite) overlap (see Fig. 1.40A.2) can significantly influence mandibular movement and the cusp design of restorations of posterior teeth. Variations in the growth and development of the jaws and in the positions of anterior teeth may result in open bite, in which vertical or horizontal discrepancies prevent teeth from contacting (see Fig. 1.40A.3).

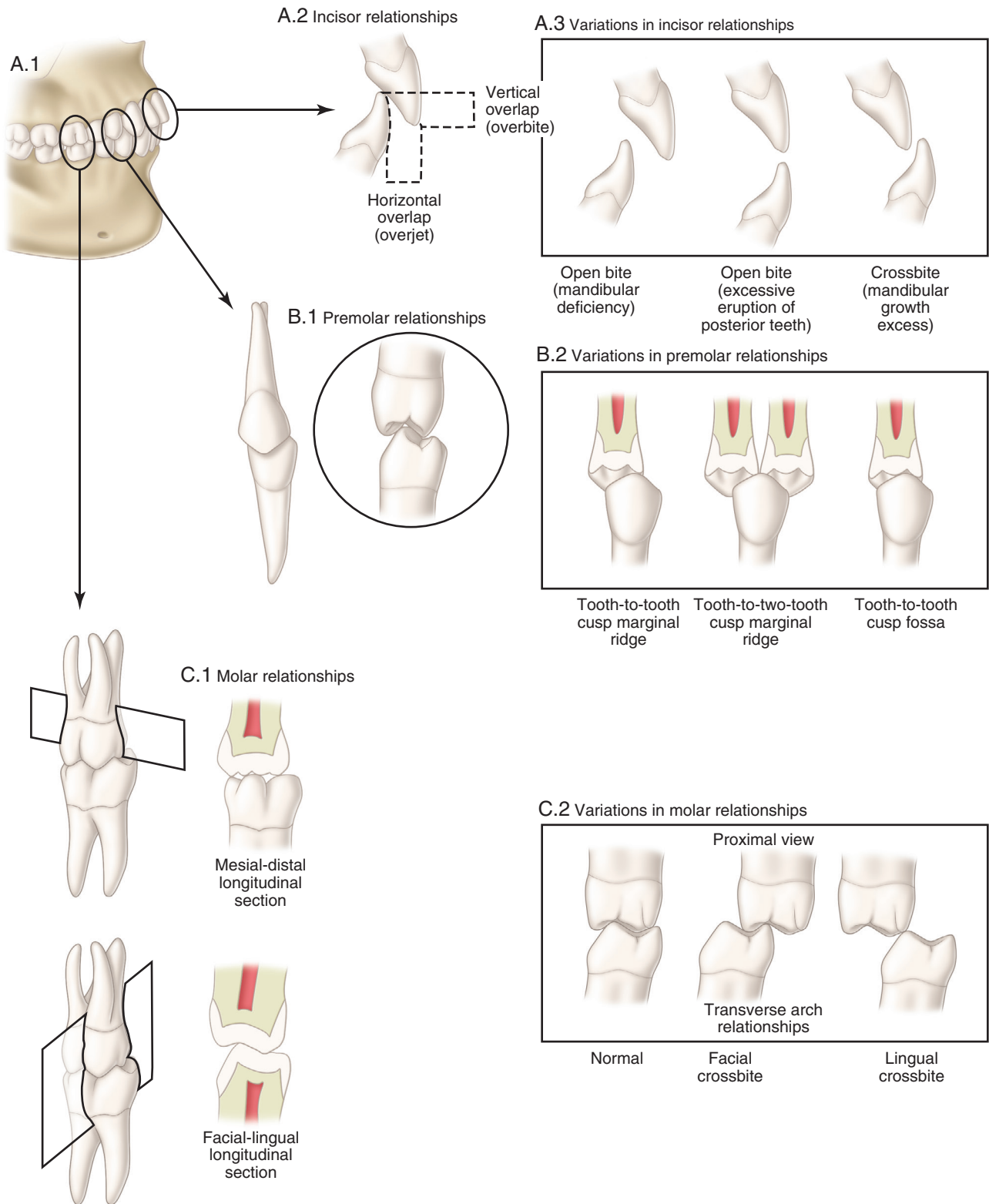
Anteroposterior Interarch Relationships

In Fig. 1.39E, the cusp interdigitation pattern of the first molar teeth is used to classify anteroposterior arch relationships using a system developed by Angle.¹³ During the eruption of teeth, the tooth cusps and fossae guide the teeth into maximal contact. Three interdigitated relationships of the first molars are commonly observed. See Fig. 1.39F for an illustration of the occlusal contacts that result from different molar positions. The location of the mesiofacial cusp of the maxillary first molar in relation to the mandibular first molar is used as an indicator in Angle classification. The most common molar relationship finds the maxillary mesiofacial cusp located in the mesiofacial developmental groove of the mandibular first molar. This relationship is termed Angle Class I. Slight posterior positioning of the mandibular first molar results in the mesiofacial cusp of the maxillary molar settling into the facial embrasure between the mandibular first molar and the mandibular second premolar. This is termed Class II and occurs in approximately 15% of the U.S. population. Anterior positioning of the mandibular first molar relative to the maxillary first molar is termed Class III and is the least common. In Class III relationships, the mesiofacial cusp of the maxillary first molar fits into the distofacial groove of the mandibular first molar; this occurs in approximately 3% of the U.S. population. Significant differences in these percentages occur in people in other countries and in different ethnic groups.

Although Angle classification is based on the relationship of the cusps, Fig. 1.39G illustrates that the location of tooth roots in alveolar bone determines the relative positions of the crowns and cusps of teeth. When the mandible is proportionally similar in size to the maxilla, a Class I molar relationship is formed; when the mandible is proportionally smaller than the maxilla, a Class



• Fig. 1.39 Dental arch relationships.



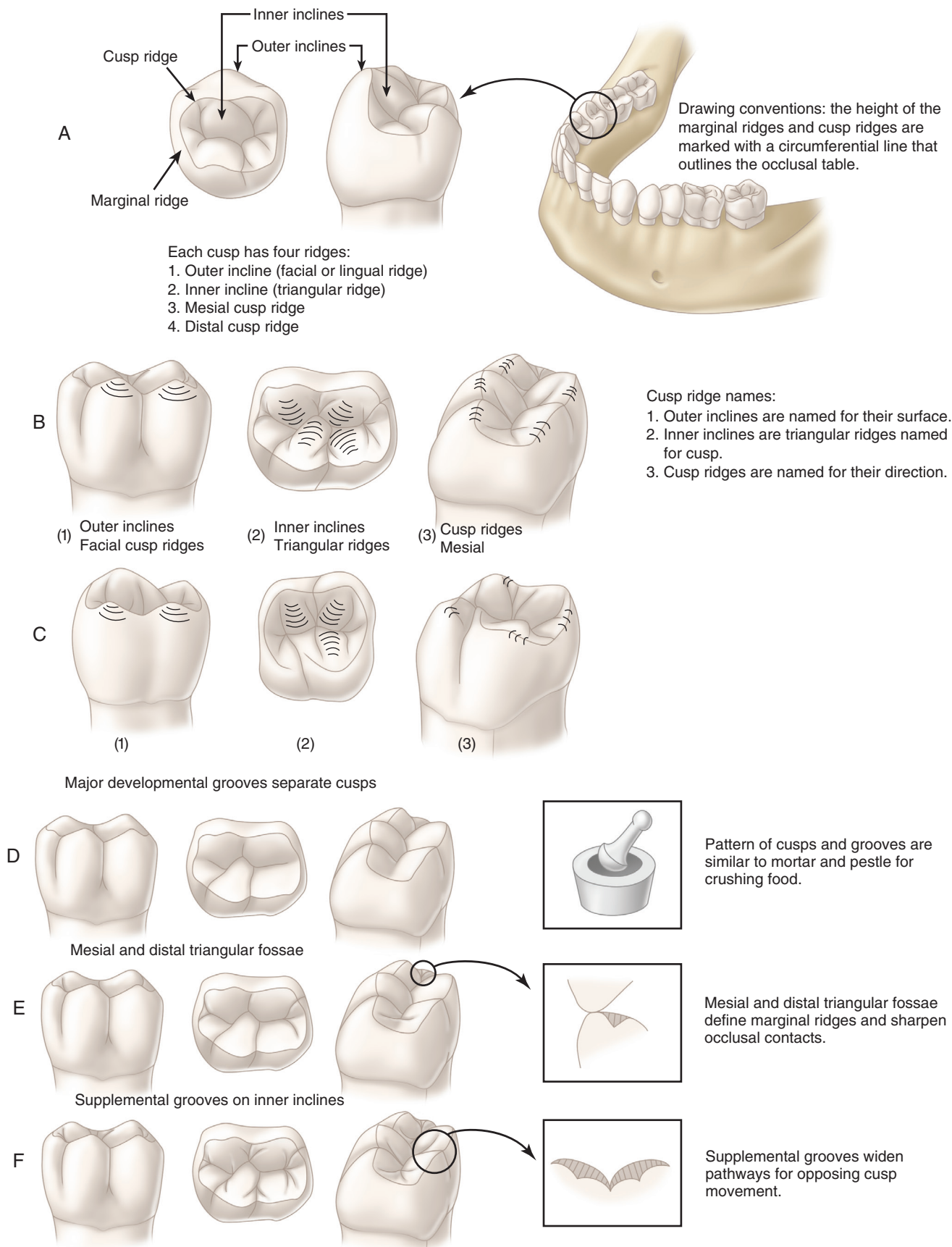
• Fig. 1.40 Tooth relationships.

II relationship is formed; and when the mandible is relatively greater than the maxilla, a Class III relationship is formed.

Interarch Tooth Relationships

Fig. 1.40 illustrates the occlusal contact relationships of individual teeth in more detail. In Fig. 1.40A.2, incisor overlap is illustrated.

The overlap is characterized in two dimensions: (1) horizontal overlap (overjet) and (2) vertical overlap (overbite). Differences in the sizes of the mandible and the maxilla can result in clinically significant variations in incisor relationships, including open bite as a result of mandibular deficiency or excessive eruption of posterior teeth, and crossbite as a result of mandibular growth excess (see



• Fig. 1.41 Common features of all posterior teeth.

Fig. 1.40A.3). These variations have significant clinical effects on the contacting relationships of posterior teeth and resultant masticatory activity during various jaw movements because the anterior teeth are not contributing to mandibular guidance.

Fig. 1.40B.1 illustrates a normal Class I occlusion, in which each mandibular premolar is located one half of a tooth width anterior to its maxillary antagonist. This relationship results in the mandibular facial cusp contacting the maxillary premolar mesial marginal ridge and the maxillary premolar lingual cusp contacting the mandibular distal marginal ridge. Because only one antagonist is contacted, this is termed *tooth-to-tooth relationship*. The most stable maxillary/mandibular tooth relationship results from the contact of the functional cusp tips against the two marginal ridges, termed *tooth-to-two-tooth contact*. Variations in the mesiodistal root position of teeth produce different relationships (see Fig. 1.40B.2). When the mandible is slightly distal to the maxilla (termed Class II tendency), each functional cusp tip occludes in a stable relationship with the opposing mesial or distal fossa; this relationship is a cusp–fossa contact.

Fig. 1.40C illustrates Class I molar relationships in more detail. Fig. 1.40C.1 shows the mandibular facial cusp tips contacting the maxillary marginal ridges and the central fossa triangular ridges. A faciolingual longitudinal section reveals how the functional cusps contact the opposing fossae and shows the effect of the developmental grooves on reducing the height of the nonfunctional cusps opposite the functional cusp tips. During lateral movements, the functional cusp is able to move through the facial and lingual developmental groove spaces without contact. Faciolingual position variations are possible in molar relationships because of differences in the growth of the width of the maxilla or the mandible.

Fig. 1.40C.2 illustrates the normal molar contact position, facial crossbite, and lingual crossbite relationships. Facial crossbite in posterior teeth is characterized by the contact of the maxillary facial cusps in the opposing mandibular central fossae and the mandibular lingual cusps in the opposing maxillary central fossae. Facial crossbite (also termed *buccal crossbite*) results in the reversal of roles of the cusps of the involved teeth. In this reversal example, the mandibular lingual cusps and maxillary facial cusps become functional cusps, and the maxillary lingual cusps and mandibular facial cusps become nonfunctional cusps. Lingual crossbite results in a poor molar relationship that provides little functional contact.

Posterior Cusp Characteristics

Four cusp ridges may be identified as common features of all cusps. The outer incline of a cusp faces the facial (or the lingual) surface of the tooth and is named for its respective surface. In the example using a mandibular second premolar (see Fig. 1.41A), the facial cusp ridge of the facial cusp is indicated by the line that points to the outer incline of the cusp. The inner inclines of the posterior cusps face the central fossa or the central groove of the tooth. The inner incline cusp ridges are widest at the base and become narrower as they approach the cusp tip. For this reason, they are termed *triangular ridges*. The triangular ridge of the facial cusp of the mandibular premolar is indicated by the arrow to the inner incline. Triangular ridges are usually set off from the other cusp ridges by one or more supplemental grooves. In Fig. 1.41B.1 and C.1, the outer inclines of the facial cusps of the mandibular and maxillary first molars are highlighted. In Fig. 1.41B.2 and C.2, the triangular ridges of the facial and lingual cusps are highlighted.

Mesial and distal cusp ridges extend from the cusp tip mesially and distally and are named for their directions. Mesial and distal cusp ridges extend downward from the cusp tips, forming the

characteristic facial and lingual profiles of the cusps as viewed from the facial or lingual aspect. At the base of the cusp, the mesial or distal cusp ridge abuts to another cusp ridge, forming a developmental groove, or the cusp ridge turns toward the center line of the tooth and fuses with the marginal ridge. Marginal ridges are elevated, the rounded ridges being located on the mesial and distal edges of the tooth's occlusal surface (see Fig. 1.41A). The occlusal table of posterior teeth is the area contained within the mesial and distal cusp ridges and the marginal ridges of the tooth. The occlusal table limits are indicated in the drawings by a circumferential line connecting the highest points of the curvatures of the cusp ridges and marginal ridges.

The unique shape of cusps produces the characteristic form of individual posterior teeth. The mandibular first molars have longer triangular ridges on the distofacial cusps, causing a deviation of the central groove (see Fig. 1.41B.2). The mesiolingual cusp of a maxillary molar is much larger than the mesiofacial cusp. The distal cusp ridge of the maxillary first molar mesiolingual cusp curves facially to fuse with the triangular ridge of the distofacial cusp (see Fig. 1.41C.2). This junction forms the oblique ridge, which is characteristic of maxillary molars. The transverse groove crosses the oblique ridge where the distal cusp ridge of the mesiolingual cusp meets the triangular ridge of the distofacial cusp.

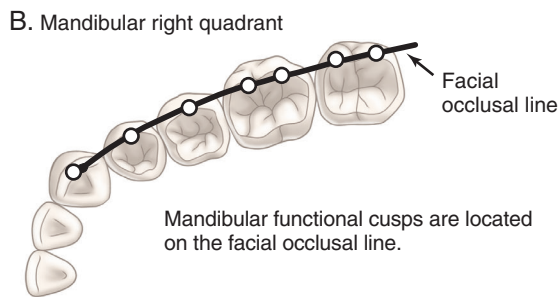
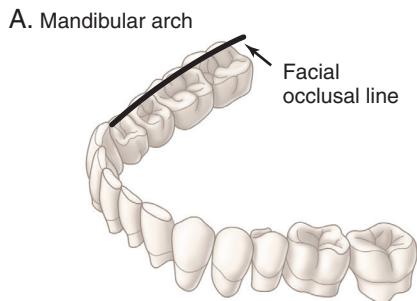
Functional Cusps

In Fig. 1.42, the lingual occlusal line of maxillary teeth and the facial occlusal line of mandibular teeth mark the locations of the functional cusps. These cusps contact opposing teeth in their corresponding faciolingual center on a marginal ridge or a fossa. Functional cusp–central fossa contact has been compared to a mortar and pestle because the functional cusp cuts, crushes, and grinds fibrous food against the ridges forming the concavity of the fossa (see Fig. 1.41D). Natural tooth form has multiple ridges and grooves ideally suited to aid in the reduction of the food bolus during chewing. During chewing, the highest forces and the longest duration of contact occur at MI. Functional cusps also serve to prevent drifting and passive eruption of teeth—hence the term *holding cusp*. The functional cusps (see Fig. 1.42) are identified by five characteristic features:¹⁴

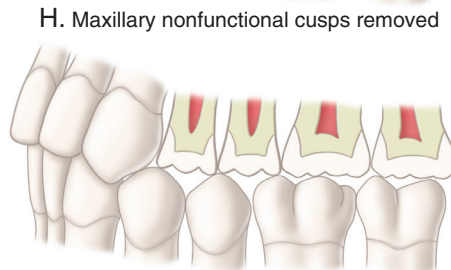
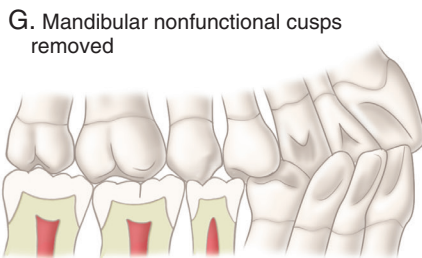
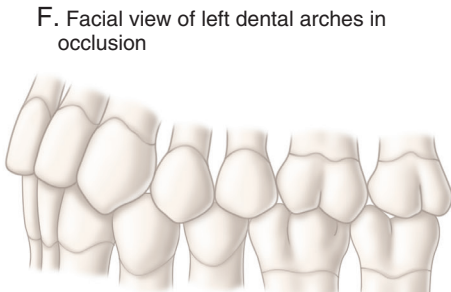
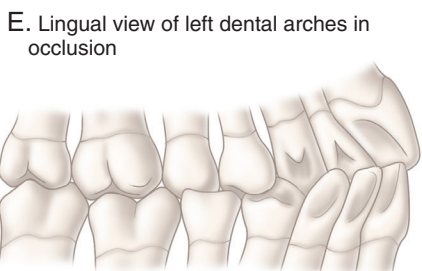
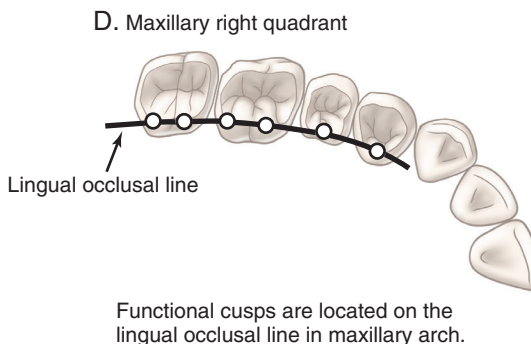
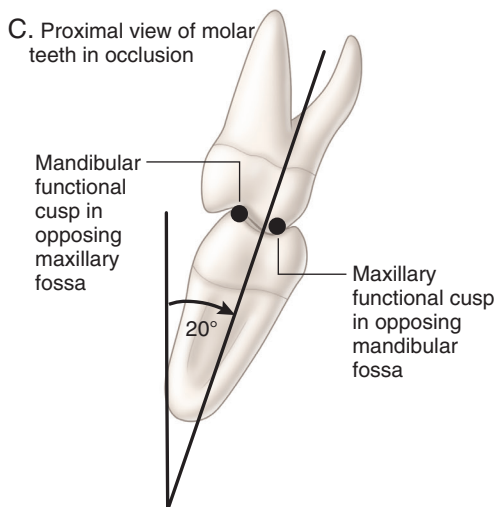
1. They contact the opposing tooth in MI.
2. They maintain the vertical dimension of the face.
3. They are nearer the faciolingual center of the tooth than nonfunctional cusps.
4. Their outer (facial) incline has the potential for contact.
5. They have broader, more rounded cusp ridges with greater dentin support than nonfunctional cusps.

Because the maxillary arch is larger than the mandibular arch, the functional cusps are located on the maxillary lingual occlusal line (see Fig. 1.42D), whereas the mandibular functional cusps are located on the mandibular facial occlusal line (see Fig. 1.42A and B). Functional cusps of both arches are more robust and better suited to crushing food than are the nonfunctional cusps. The lingual tilt of posterior teeth increases the relative height of the functional cusps with respect to the nonfunctional cusps (see Fig. 1.42C), and the central fossa contacts of the functional cusps are obscured by the overlapping nonfunctional cusps (see Fig. 1.42E and F). A schematic showing removal of the nonfunctional cusps allows the functional cusp–central fossa contacts to be studied (see Fig. 1.42G and H). During fabrication of restorations, it is important that functional cusps are not contacting opposing teeth in a manner that results in lateral deflection. Rather, restorations should provide contacts on plateaus or smoothly concave fossae

Synonyms for functional cusps include:
 1. Centric cusps
 2. Holding cusps
 3. Stamp cusps



The mandibular arch is smaller than the maxillary arch, so the functional cusps are located on the facial occlusal line. The mandibular lingual cusps that overlap the maxillary teeth are nonsupporting cusps.



Maxillary functional cusps occluding in opposing fossae and on marginal ridges

Mandibular functional cusps occluding in opposing fossae and on marginal ridges

- Functional cusp features:
1. Contact opposing tooth in MI
 2. Support vertical dimension
 3. Nearer faciolingual center of tooth than nonsupporting cusps
 4. Outer incline has potential for contact
 5. More rounded than nonsupporting cusps

• Fig. 1.42 Functional cusps.

so that masticatory forces are directed approximately parallel to the long axes of teeth (i.e., approximately perpendicular to the occlusal plane).

Nonfunctional Cusps

Fig. 1.43 illustrates that the nonfunctional cusps form a lingual occlusal line in the mandibular arch (see Fig. 1.43D) and a facial occlusal line in the maxillary arch (see Fig. 1.43B). Nonfunctional cusps overlap the opposing tooth without contacting the tooth. Nonfunctional cusps are located, when viewed in the anteroposterior plane, in facial (lingual) embrasures or in the developmental groove of opposing teeth, creating an alternating arrangement when teeth are in MI (see Fig. 1.43E and F). The maxillary premolar nonfunctional cusps also play an essential role in esthetics. In the occlusal view, the nonfunctional cusps are farther from the faciolingual center of the tooth than are the functional cusps and have less dentinal support. Nonfunctional cusps have sharper cusp ridges that may serve to shear food as they pass close to the functional cusp ridges during chewing strokes. The overlap of the maxillary nonfunctional cusps helps keep the soft tissue of the cheek out and away from potential trauma from the occlusal table. Likewise, the overlap of the mandibular nonfunctional cusps helps keep the tongue out from the occlusal table. Therefore, the position of the maxillary and mandibular nonfunctional cusps help to prevent self-injury during chewing.

Mechanics of Mandibular Motion

Mandible and Temporomandibular Joints

The mandible articulates with a depression in each temporal bone called *glenoid fossa*. The joints are termed *temporomandibular joints (TMJs)* because they are named for the two bones (temporal and mandible) forming the articulation. The TMJs allow the mandible to move in all three planes (Fig. 1.44A).

A TMJ is similar to a ball-and-socket joint, but it differs from a true mechanical ball-and-socket joint in some very important aspects. The ball part (the mandibular condyle) is smaller than the socket (the glenoid fossa) (see Fig. 1.44B). The space resulting from the size difference is filled by a tough, pliable, and movable stabilizer termed the *articular disc*. The disc separates the TMJ into two articulating surfaces lubricated by synovial fluid in the superior and inferior joint spaces. Rotational opening of the mandible occurs as the condyles rotate under the discs (see Fig. 1.44C). Rotational movement occurs between the inferior surface of the discs and the condyle. During wide opening or protrusion of the mandible, the condyles move or slide anteriorly in addition to the rotational opening (see Fig. 1.44D and E). The TMJ is referred to as a *ginglymoarthrodial joint* because it has hinge (ginglymus) capability as well as sliding/gliding/translating (arthrodial) capability.

The discs move anteriorly with the condyles during opening and produce a sliding movement in the superior joint space between the superior surface of the discs and the articular eminences (see Fig. 1.44B). TMJs allow free movement of the condyles in the anteroposterior direction but resist lateral displacement. The discs are attached firmly to the medial and lateral poles of the condyles in normal, healthy TMJs (see Fig. 1.45B). The disc–condyle arrangement of the TMJ allows simultaneous sliding and rotational movement in the same joint.

Because the mandible is a semirigid, U-shaped bone with joints on both ends, movement of one joint produces a reciprocal movement in the other joint. The disc–condyle complex is free to move

anteroposterior, providing sliding movement between the disc and the glenoid fossa. One condyle may move anteriorly, while the other remains in the fossa. Anterior movement of only one condyle produces reciprocal lateral rotation in the opposite TMJ.

The TMJ does not behave like a rigid joint as those on articulators (mechanical devices used by dentists to simulate jaw movement and reference positions [see the subsequent section on *Articulators and Mandibular Movements*]). Because soft tissues cover the two articulating bones and an intervening disc composed of soft tissue is present, some resilience is to be expected in the TMJs. In addition to resilience, normal, healthy TMJs have flexibility, allowing small posterolateral movements of the condyles. In healthy TMJs, the movements are restricted to slightly less than 1 mm laterally and a few tenths of a millimeter posteriorly.

When morphologic changes occur in the hard and soft tissues of a TMJ because of disease, the disc–condyle relationship is possibly altered in many ways, including distortion, perforation, or tearing of the disc, and remodeling of the soft tissue articular surface coverings or their bony support. Diseased TMJs have unusual disc–condyle relationships, different geometry, and altered jaw movements and reference positions. Textbooks on TMJ disorders and occlusion should be consulted for information concerning the evaluation of diseased joints.¹⁵ The remainder of this discussion of the movement and position of the mandible is based on normal, healthy TMJs and does not apply to diseased joints.

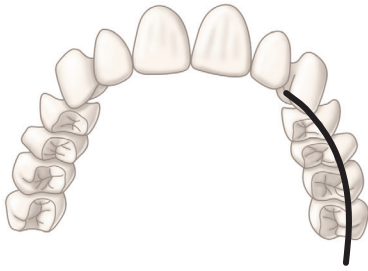
Review of Normal Masticatory Muscle Function and Mandibular Movement

Masticatory muscles work together to allow controlled, subtle movements of the mandible. The relative amount of muscle activity depends on the interarch relationships of maxillary and mandibular teeth as well as the amount of resistance to movement.^{16–19} Primary muscles involved in mandibular movements include the anterior temporalis, middle temporalis, posterior temporalis, superficial masseter, deep masseter, superior lateral pterygoid, inferior lateral pterygoid, medial pterygoid, and digastric muscles.^{17,18,20} The suprahyoid, infrahyoid, mylohyoid, and geniohyoid muscles also are involved in mandibular movements but not usually included in routine clinical examinations.^{18,21} The relative amount of muscle activity of the various muscles has been identified through the use of electromyographic technology, in which electrodes were placed in the evaluated muscles,^{17,18,22} as well as on the skin immediately adjacent to the muscles of interest.^{12,17,18,20,21–30} The strategic three-dimensional arrangement of the muscles and the corresponding force vectors allow for the complete range of finely controlled mandibular movements. The reader should consult an appropriate human anatomy textbook to identify the location, size, shape, three-dimensional orientation, and bony insertion of the various muscles discussed in this section.

Simple jaw opening requires the activation of digastric and inferior lateral pterygoid muscles.^{17,18,22} Fine control of opening is accomplished by simultaneous mild antagonistic activity of the medial pterygoid.^{17,18} When resistance is applied to jaw opening, mild masseter activation allows further stabilization and fine control.^{17,18}

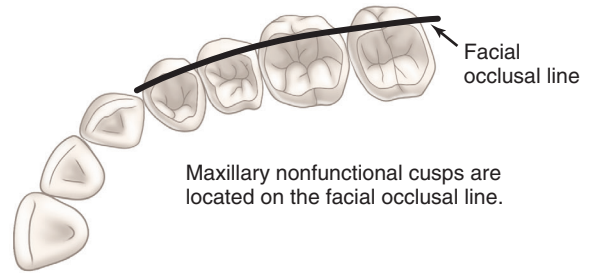
Jaw closure requires the activation of the masseter and medial pterygoid.¹⁸ Once teeth come into contact, the temporalis (anterior, middle, and posterior) muscles activate as well.^{17,18} The masseter, medial pterygoid, and temporalis muscles act to elevate the mandible and are generally referred to as *elevator muscles*. Clenching involves maximum activation of the masseter and temporalis, moderate activation of the medial pterygoid and superior lateral pterygoid,

A. Maxillary arch



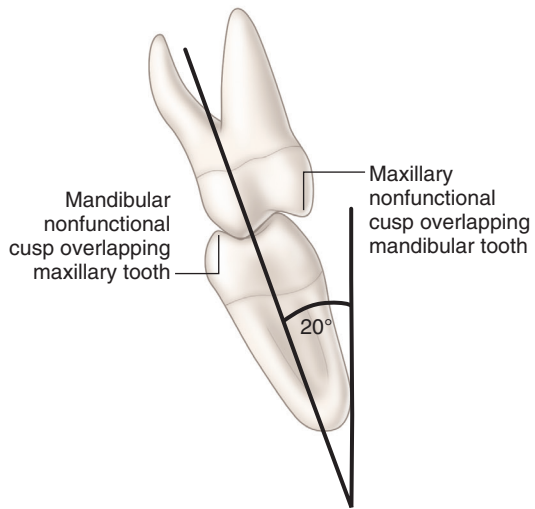
The maxillary arch is larger than the mandibular arch causing the maxillary facial line (nonfunctional cusps) to overlap the mandibular teeth.

B. Maxillary left quadrant



Maxillary nonfunctional cusps are located on the facial occlusal line.

C. Molar teeth in occlusion

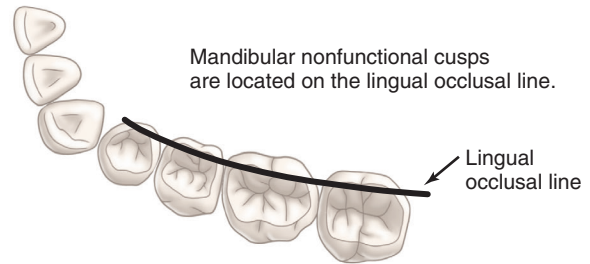


Mandibular nonfunctional cusp overlapping maxillary tooth

Maxillary nonfunctional cusp overlapping mandibular tooth

20°

D. Mandibular left quadrant

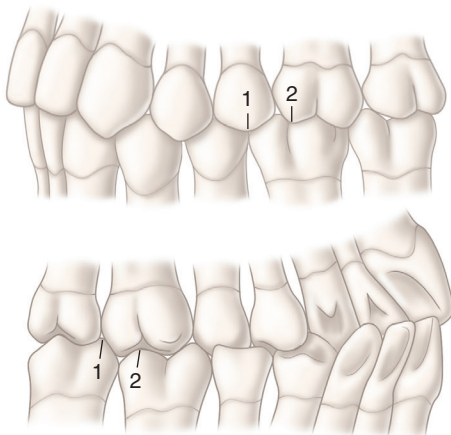


Mandibular nonfunctional cusps are located on the lingual occlusal line.

Nonfunctional cusp features:

1. Do not contact opposing tooth in MI
2. Keep soft tissue of tongue or cheek off occlusal table
3. Farther from faciolingual center of tooth than supporting cusps
4. Outer incline has no potential for contact
5. Have sharper cusp ridges than supporting cusps

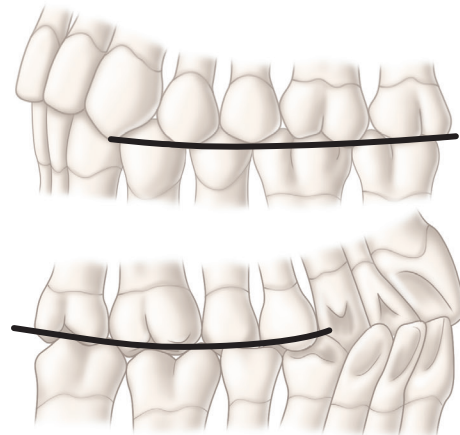
E. Views of left dental arches in occlusion showing interdigitation of nonfunctional cusps



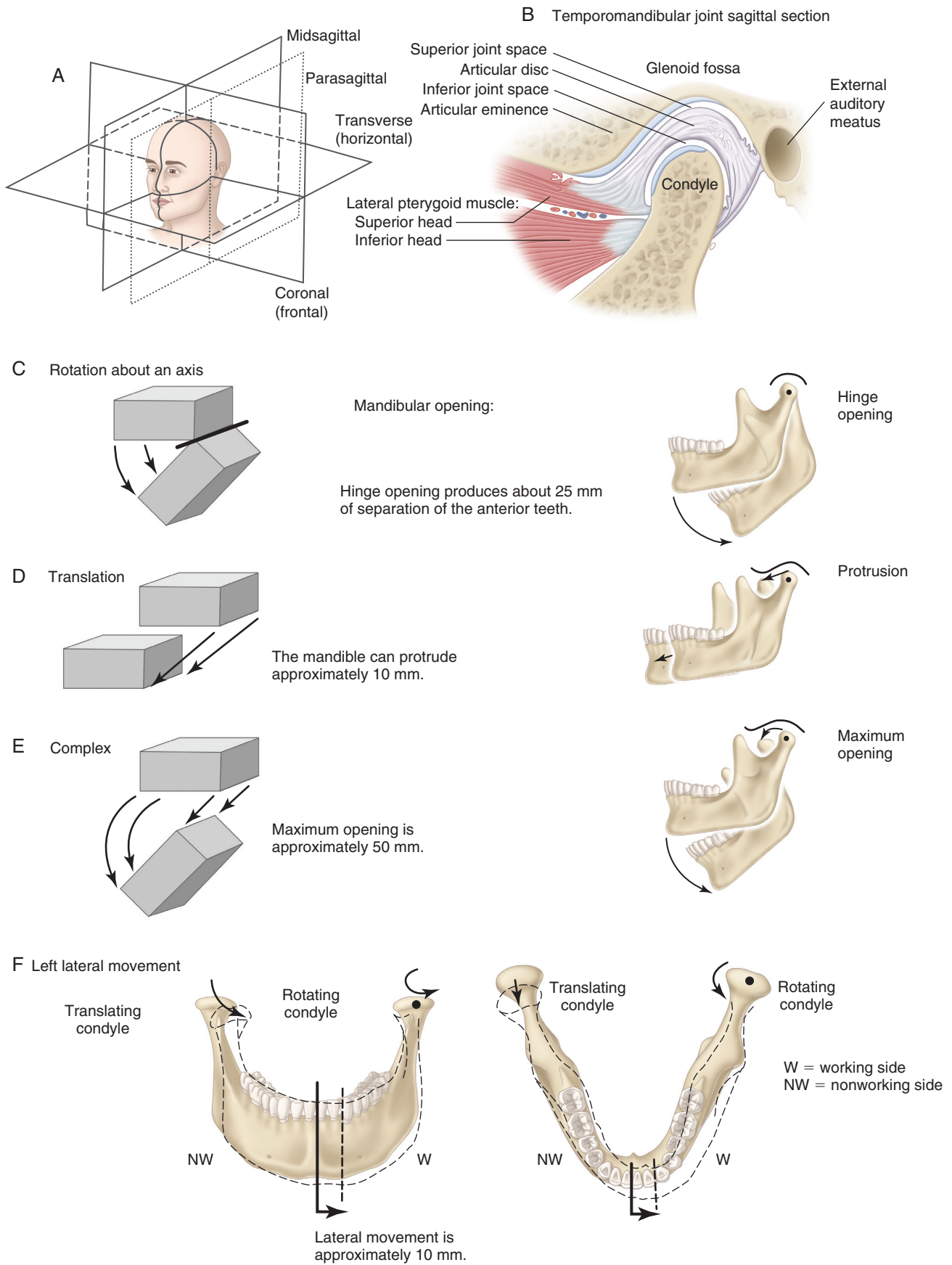
Nonfunctional cusp location:

1. Opposing embrasure
2. Opposing developmental groove

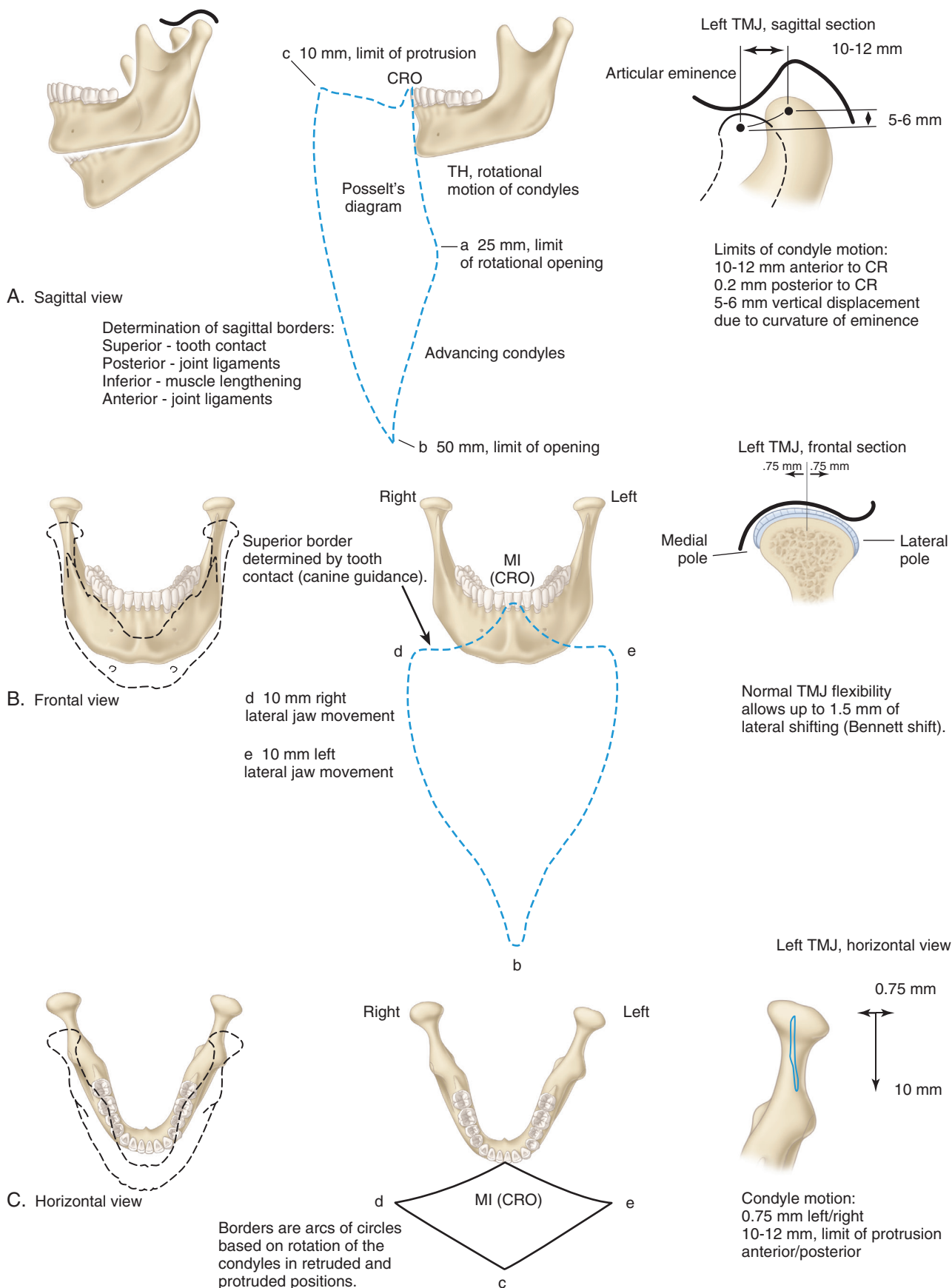
F. Views of left dental arches in occlusion showing facial and lingual occlusal lines



• Fig. 1.43 Nonfunctional cusps.



• Fig. 1.44 Types and directions of mandibular movements.



• **Fig. 1.45** Capacity of mandibular movement. (Mandible drawings are not to scale with border diagrams.) CO=MI (i.e., there is no functional shift and, therefore, is termed centric relation occlusion [CRO]).

and recruitment of the inferior lateral pterygoid, digastrics, and mylohyoid muscles.^{17,18,22} In general, the superficial masseter has slightly higher activity than the deep masseter during clenching.²⁰ Coactivation of cooperating and antagonistic muscles allows for controlled force to be applied to teeth.¹⁷

Protrusion requires maximum bilateral activation of the inferior lateral pterygoid, with moderate activation of the medial pterygoid, masseter, and digastric muscles. During protrusion minimal activation of the temporalis and superior lateral pterygoid occurs. The superior lateral pterygoid has muscle fibers that insert into the temporomandibular disc as well as the neck of the mandibular condyle (see Fig. 1.44).²² It is important to note that minimal activation of the superior lateral pterygoid is necessary if the temporomandibular disc is to rotate to the top of the condylar head as the condyle translates down the articular eminence during mandibular protrusive or excursive movements.¹⁷

Incisal biting with posterior disclusion requires maximum bilateral activity of the superficial masseter to force the incisors toward each other, as well as maximum activity of the inferior lateral pterygoid to maintain the protruded position of the condylar head down the slope of the articular eminence.¹⁷ Incisal biting also requires moderate activity of the anterior temporalis, medial pterygoid, anterior digastric, and superior lateral pterygoid.¹⁷ Note that the shift in the level of activity of the superior lateral pterygoid from protrusion to incisal biting indicates a dual role in condylar positioning and temporomandibular disc positioning or stabilization. The middle and posterior temporalis regions have minimal activity during incisal biting.¹⁸

Retrusion of the mandible requires bilateral maximum activation of the posterior and middle temporalis as well as moderate activity of the anterior temporalis and anterior digastric.^{17,18} The superior lateral pterygoid is maximally active when the mandible is retruded and posterior teeth are clenched.¹⁷ The masseter has minimal activity in retrusion.¹⁷ The inferior lateral pterygoid and the medial pterygoid have minimal to no activity during retrusion.^{17,18}

Excursive movement of the mandible to the right requires moderate to maximal activity of the left inferior lateral pterygoid and medial pterygoid muscles as well as the right posterior temporalis, middle temporalis, and anterior digastric.¹⁷⁻¹⁹ In addition to these, the right superior lateral pterygoid, right anterior temporalis, and left anterior digastric are minimally to moderately active.¹⁷⁻¹⁹ Activation of the right superior lateral pterygoid provides resistance to right condyle distalization as well as positional support of the right temporomandibular disc. The right superficial masseter, right inferior lateral pterygoid, right medial pterygoid, left superior lateral pterygoid, left anterior temporalis, left middle temporalis, left posterior temporalis, and left superficial masseter all have minimal activity.¹⁷⁻¹⁹ Minimal activity of the left superior lateral pterygoid allows the disc to shift distally, as needed, so as to remain between the condylar head and the articular eminence while translation or rotation of the left condylar head occurs. Activation of the elevator muscles on the left side provides for the translating left condyle–disc complex to remain in contact with the articular eminence. Movement of the mandible to the left follows the same pattern of coordinated muscle activity except in reverse.

Wide opening requires bilateral moderate to maximal activity of the inferior lateral pterygoid and anterior digastric muscles.¹⁷ In addition to these, the medial pterygoid muscles are minimally to moderately active.¹⁷ The temporalis, masseter, and superior lateral pterygoid muscles have minimal to no activity during wide opening.^{17,18}

During mastication, the typical mandibular movement involves opening with corresponding bilateral anterior, inferior, and rotating condylar motion.^{12,51} As closure begins, the entire mandible moves laterally.¹² As closure continues, the working-side condyle shifts back to its terminal hinge position before the teeth occlude and remains nearly stationary.¹² As the closure continues, the working-side condyle shifts medially while the nonworking-side condyle shifts superiorly, distally, and laterally to its terminal hinge position.¹² The medial shift of the working-side condyle may be caused by the influence of the superior lateral pterygoid muscle contraction. The opening and closing paths of the incisors vary from individual to individual and also depend on the consistency of the food being masticated.¹² The realistic normal lower limit for the incisal opening in patients between 10 and 70 years of age is 40 mm.³²

To describe mandibular motion, its direction and length must be specified in three mutually perpendicular planes. By convention, these planes are sagittal, coronal (frontal), and transverse (horizontal) (see Fig. 1.44A). The midsagittal plane is a vertical (longitudinal) plane that passes through the center of the head in an anteroposterior direction. A vertical plane off the center line, such as a section through the TMJ, is termed *parasagittal plane*. The coronal plane is a vertical plane perpendicular to the sagittal plane. The transverse plane is a horizontal plane that passes from anterior to posterior and is perpendicular to the sagittal and frontal planes. Mandibular motion is described in each of these planes.

Types of Motion

Centric relation (CR), in healthy TMJs, is the location of the mandible when the condyles are positioned superiorly and anteriorly in the glenoid fossae. In CR, the thinnest avascular portion of the TMJ discs are in an anterosuperior position on the condylar head, and are adjacent to the beginning of the slopes of the articular eminences (see Fig. 1.44B). This position is independent of tooth contacts.

Rotation is a simple motion of an object around an axis (see Fig. 1.44C). The mandible is capable of rotation about an axis through centers located in the condyles. The attachments of the discs to the poles of the condyles permit the condyles to rotate under the discs. Rotation with the condyles positioned in CR is termed *terminal hinge (TH) movement*. Maximum rotational opening in TH is limited to approximately 25 mm measured between the incisal edges of anterior teeth. Initial tooth contact during a TH closure provides a reference point termed *centric occlusion (CO)*. Many patients have a small slide from CO to MI, referred to as a *functional shift*, which may have forward and lateral components. CR is used in dentistry as a reproducible reference position for major restorative reconstruction of the maxillary and mandibular occlusal planes and also when fabricating full dentures. The reproducibility of the CR position allows the establishment of simultaneous contact of all functional cusps in maximum intercuspation while the mandible is in CR. This occlusion is termed *centric relation occlusion (CRO)*. CRO allows maximum osseous support of the mandibular condyles and even distribution of occlusal loading forces, generated by the elevator muscles, across the whole dentition. The functional cusps in CRO are termed *centric cusps*. The non-functional cusps in CRO are termed *noncentric cusps*.

Translation is the bodily movement of an object from one place to another (see Fig. 1.44D). The mandible is capable of translation by the anterior movement of the disc–condyle complex from the TH position forward and down the articular eminence and back. Simultaneous, direct anterior movement of both condyles, or mandibular forward thrusting, is termed *protrusion*. The pathway followed by anterior teeth during protrusion may not be smooth

or straight because of contact between anterior teeth and sometimes posterior teeth. (See the superior border of Posselt diagram in Fig. 1.45A.) Protrusion is limited to approximately 10 mm by the ligamentous attachments of masticatory muscles and the TMJs.

Fig. 1.44E illustrates complex motion, which combines rotation and translation in a single movement. Most mandibular movement during speech, chewing, and swallowing consists of rotation and translation. The combination of rotation and translation allows the mandible to open 50 mm or more.

Fig. 1.44F illustrates the left lateral movement of the mandible. It is the result of forward translation of the right condyle and rotation of the left condyle. Right lateral movement of the mandible is the result of forward translation of the left condyle and rotation of the right condyle.

Capacity of Motion of the Mandible

In 1952, Posselt recorded mandibular motion and developed a diagram (termed *Posselt diagram*) to illustrate it (see Fig. 1.45A).³³ By necessity, the original recordings of mandibular movement were done outside of the mouth, which magnified the vertical dimension but not the horizontal dimension. Modern systems using digital computer techniques can record mandibular motion in actual time and dimensions and then compute and draw the motion as it occurred at any point in the mandible and teeth.¹² This makes it possible to accurately reconstruct mandibular motion simultaneously at several points. Three of these points are particularly significant clinically: incisor point, molar point, and condyle point (Fig. 1.46A).³⁴ The incisor point is located on the midline of the mandible at the junction of the facial surface of mandibular central incisors and the incisal edge. The molar point is the tip of the mesiofacial cusp of the mandibular first molar on a specified side. The condyle point is the center of rotation of the mandibular condyle on the specified side.

Limits of Mandibular Motion: The Borders

In Fig. 1.45A, the limits for movement of the incisor point are illustrated in the sagittal plane. The mandible is not drawn to scale with the drawing of the sagittal borders. This particular diagram is drawn in CRO (i.e., CO coincides with MI). The starting point for this diagram is CRO, the contact of all teeth when the condyles are in CR. The posterior border of the diagram from CRO to *a* in Fig. 1.45A is formed by the rotation of the mandible around the condyle points. This border from CRO to *a* is the TH movement. *Hinge axis* is the term used to describe an imaginary line connecting the centers of rotation in the condyles (condyle points) and is useful for reference to articulators (see upcoming section, *Articulators and Mandibular Movements*). The hinge-axis position (also referred to as CR) is a reproducible reference position and rotational, mandibular closure movement on this axis is used when restorative procedures require recreation of the occlusal relationships of multiple teeth. The inferior limit to this hinge opening occurs at approximately 25 mm and is indicated by *a* in Fig. 1.45A. The superior limit of the posterior border occurs at tooth contact and is identified as CRO.

At point *a* in Fig. 1.45A, further rotation of the condyles is impossible because of the stretch limits of the joint capsule, ligamentous attachments to the condyles, and the mandible-opening muscles. Further opening can be achieved only by translation of the condyles anteriorly, producing the line *a-b*. Maximum opening (point *b*) in adults is approximately 50 mm. These measures are important diagnostically. Mandibular opening limited to 25 mm

suggests blockage of condylar translation, usually the result of a disc disorder(s). Limitation of opening in the 35- to 45-mm range suggests masticatory muscle hypertonicity. The line CRO-*a-b* represents the maximum retruded opening path. This is the posterior border, or the posterior limit of mandibular opening. The line *b-c* represents the maximum protruded closure. This is achieved by a forward thrust of the mandible that keeps the condyles in their maximum anterior positions while closing the mandible.

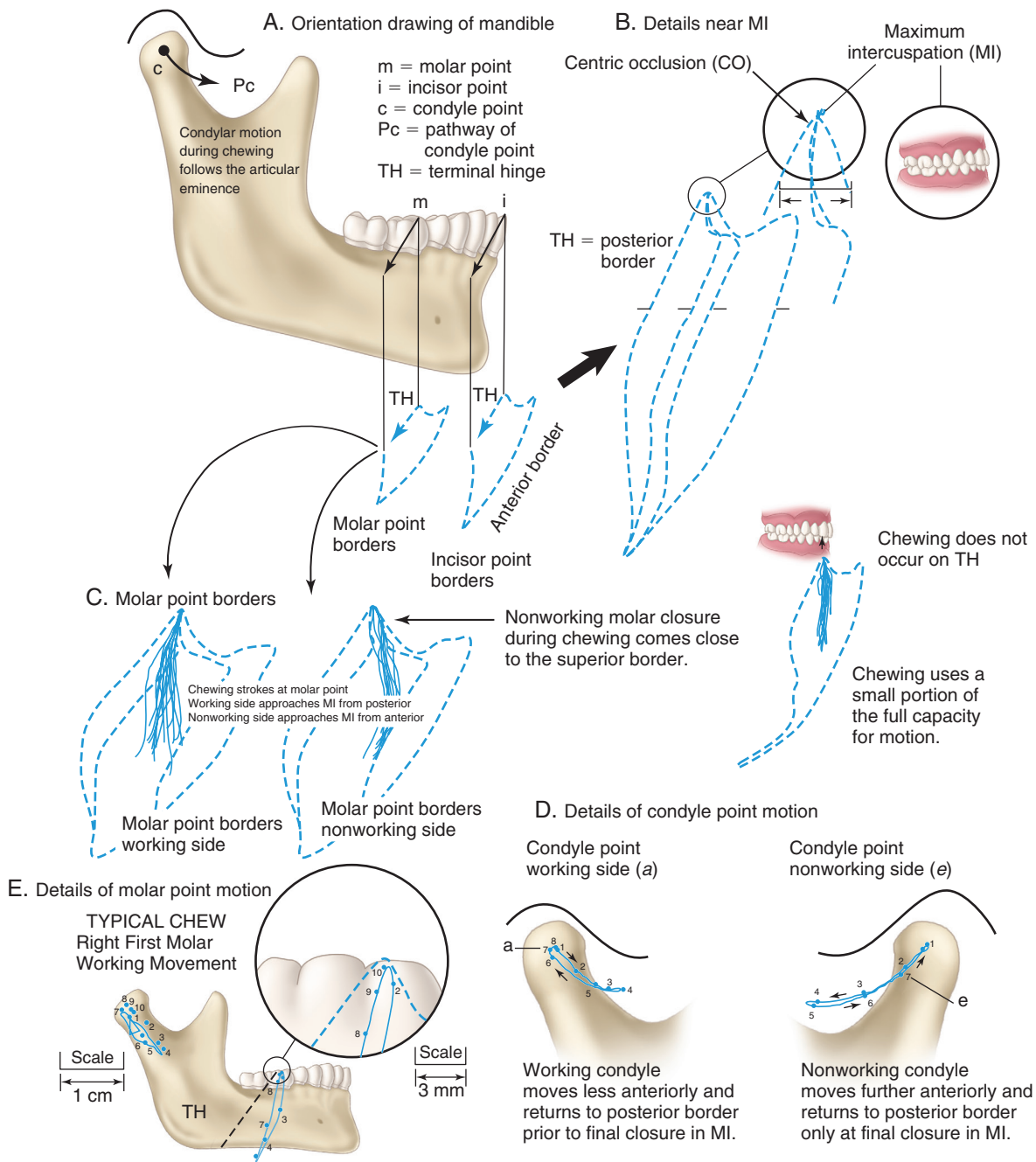
Retrusion, or posterior movement of the mandible, results in the irregular line *c-CRO*. The irregularities of the superior border are caused by tooth contacts; the superior border is a tooth-determined border. Protrusion is a reference mandibular movement starting from CRO and proceeding anteriorly to point *c*. Protrusive mandibular movements are used by dentists to evaluate occlusal relationships of teeth and restorations. The complete diagram, CRO-*a-b-c-CRO*, represents the maximum possible motion of the incisor point in all directions in the sagittal plane. The area of most interest to dentists is the superior border produced by tooth contact. (Mandibular movement in the sagittal plane is illustrated in more detail in Fig. 1.46.)

The motion of the condyle point during chewing is strikingly different from the motion of the incisor point. Motion of the condyle point is a curved line that follows the articular eminence. The maximum protrusion of the condyle point is 10 to 12 mm anteriorly when following the downward curve of the articular eminence. The condyle point does not drop away from the eminence, as a result of controlled/coordinated elevator muscle activity, during mandibular movements. Chewing movements in the sagittal plane are characterized by a nearly vertical up-and-down motion of the incisor point, whereas the condyle points move anteriorly and then return posteriorly over a curved surface (see Fig. 1.46B).

In the frontal view shown in Fig. 1.45B, the incisor point and chin are capable of moving about 10 mm to the left or right. This lateral movement—or excursion—is indicated by the lines MI-*d* to the right and MI-*e* to the left. Points *d* and *e* indicate the limit of the lateral motion of the incisor point. Lateral movement is often described with respect to only one side of the mandible for the purpose of defining the relative motion of mandibular teeth to maxillary teeth. In a left lateral movement, the left mandibular teeth move away from the midline, and the right mandibular teeth move toward the midline.

Mandibular pathways directed away from the midline are termed *working* (synonyms include *laterotrusion* and *functional*), and mandibular pathways directed toward the midline are termed *nonworking* (synonyms include *mediotrusion*, *nonfunctional*, and *balancing*). The terms *working* and *nonworking* are based on observations of chewing movements in which the mandible is seen to shift during closure toward the side of the mouth containing the food bolus. The side of the jaw where the bolus of food is placed is termed *the working side*. The working side is used to crush food, whereas the nonworking side is without a food bolus. Working side also is used in reference to jaws or teeth when the patient is not chewing (e.g., in guided test movements directed laterally). The term also may identify a specific side of the mandible (i.e., the side toward which the mandible is moving). During chewing, the working-side closures start from a lateral position and are directed medially to MI.

The left lateral mandibular motion indicated by the line MI-*e* (see Fig. 1.45B) is the result of rotation of the left condyle (working-side condyle) and translation of the right condyle (nonworking-side condyle) to its anterior limit (see Fig. 1.44F). The translation of



• **Fig. 1.46** Mandibular capacity for movement: sagittal view. CO≠MI (i.e., there is a functional shift).

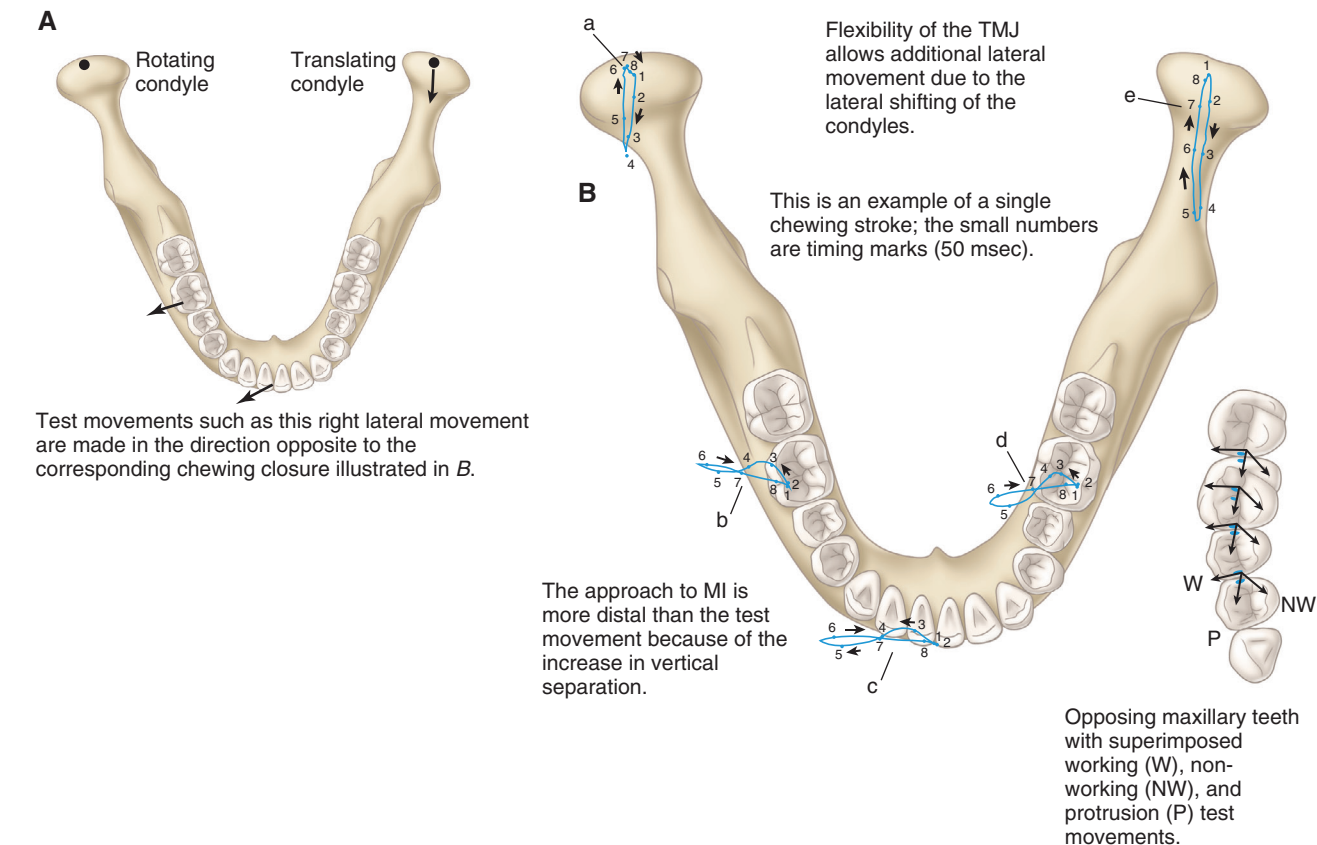
the nonworking condyle in a right lateral motion of the mandible can be seen in the horizontal view in Fig. 1.47A and B. The line *e-b* in Fig. 1.45B is completed by mandibular opening that is the result of rotation of both condyles and translation of the working condyle to its maximum anterior position. The line *b-d-MI* represents similar motions on the right side.

The vertical displacement in the incisor point line from MI to *e* or *d*, shown in Fig. 1.45B, is the result of teeth, usually canines, gliding over each other. Vertical displacement of the mandible secondary to gliding contact of canine teeth is termed *canine guidance* and has significance for restorative procedures. The gliding tooth contact supplied by canine guidance provides some of the vertical separation of posterior teeth during lateral jaw movements and prevents potentially damaging collisions of their cusps secondary

to the increased elevator muscle activity that occurs when posterior teeth come into contact. When the canine guidance is shallow, the occlusal surface of posterior teeth must be altered to prevent potentially damaging contacts during lateral or protrusive movements.

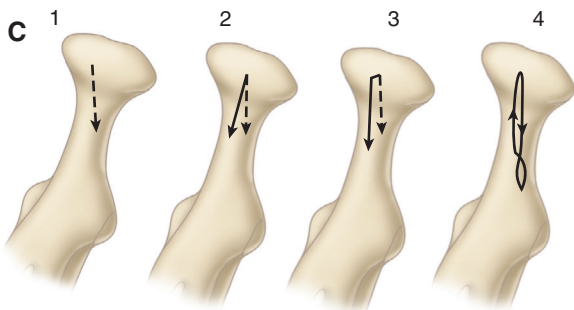
Flexibility in the TMJs allows the condyles to move slightly to the working side during the closing stroke. This lateral shift of the condylar head, illustrated in the frontal view of a right TMJ in Fig. 1.45B, is termed *Bennett shift* or *lateral shift* and varies from patient to patient (see Fig. 1.47B–D). The magnitude of the shift in normal TMJs varies from 0 to 1.5 and normally has little effect on posterior teeth. Excessive lateral shift may be associated with morphologic changes of the TMJs. Excessive lateral condylar shifting coupled with shallow canine guidance poses a significant problem,

Lateral movement is produced by anterior translation of one condyle, producing rotation about the center in the opposite condyle.

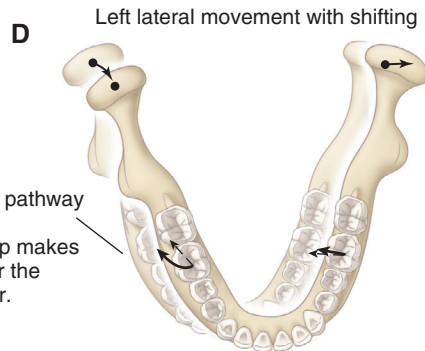


Nonworking condyle movement:

1. Condylar translation with rotation about the center of the opposite condyle
2. Solid line indicates the change in the condylar path due to progressive shifting of the center of rotation in the opposite condyle
3. Solid line indicates the condylar path resulting from immediate shifting of the center of rotation of the opposite condyle
4. Observed motion of the condyle during chewing: note shifting as closing is initiated and the return to normal position at the end of closure



- Effect of shifting at first molar:
1. Little change on working side
 2. Wide lateral motion on nonworking side



• Fig. 1.47 Mandibular capacity for movement: horizontal view.

however, for restorative procedures because the resulting lateral mandibular movements are flat; consequently, little separation of posterior teeth occurs, resulting in increased contact of posterior teeth as well as associated increased elevator muscle activity.

In Fig. 1.45C, the horizontal view illustrates the capability of the mandible to translate anteriorly. Extreme left lateral motion is indicated by MI-*e* produced by rotation of the left condyle (working condyle) and translation of the right condyle (nonworking condyle) to its anterior limit. From point *e*, protrusion of the left condyle moves the incisor point to *c*, the maximum protruded position where both condyles have translated.

Sagittal View

In Fig. 1.46, the drawing of the mandible is used to orient the sagittal border diagrams in a patient who has a functional shift between CO and MI. Recall CO is the tooth contact that occurs when the TMJs are in CR and that, in many patients, a small anterior or anterolateral slide may occur from CO to MI. Projected below the mandible are diagrams of the incisor point (*i*) and molar point (*m*) borders (see Fig. 1.46A). The molar point borders are similar to the incisor point diagram but are shorter in the vertical dimension because the molar point is closer to the TMJ. Closure of the jaw on the posterior border is termed *TH closure*. TH closure is a simple arc of a circle with a radius equal to the length from the incisor point to the center of the hinge axis (condyle point *c*). The area near MI is enlarged to illustrate the details of the TH closure (see Fig. 1.46B). CO and MI are located fairly close to each other in this case. In the magnified view, teeth may be seen to guide the mandible from CO to MI. The gliding (sliding) functional shift typically is 1 to 2 mm long and may occur on any of the posterior teeth. The horizontal component of this slide varies and may only be a few tenths of a millimeter. The primary concern is that the functional shift may position the condyle(s) on the slope of the articular eminence, a position that requires constant protrusive muscle activity to maintain.^{17,22}

The clinical significance of the shift between CO and MI has been a source of debate in dentistry, resulting in extensive literature on the topic.^{35,36} Clinical ramifications may include an increased risk of the development of pathologic changes in the TMJs and/or pain associated with the muscles of mastication. It has been observed that asymmetrical shifts between CO and MI were related to symptoms and signs of temporomandibular disorders, whereas symmetrical shifts were not.³² It has been noted that increasing symptoms and signs of temporomandibular disorders were associated with increasing functional shift distance from CO to MI.³⁷ However, a shift of greater than 2 mm, mediotrusive posterior tooth interferences, and a large overjet were only weakly associated with masticatory muscle pain, suggesting other factors in addition to occlusal relationships may be involved.^{38,39} Failure to recognize that some patients have damaged TMJs may further complicate the determination of the clinical significance of a CO–MI slide. Damage to the TMJs as a consequence of arthritic processes or internal derangements may change the relationship of CO to MI.

Chewing movements at the incisor point involve an almost vertical opening and a loop slightly to the posterior on closing, using only a small percentage of the total area of the sagittal border diagram. During chewing, the only border contact occurs at MI. The closing strokes never approach TH, indicating that at least one condyle (on the nonworking side) remains advanced during the closing stroke. The condyle point moves along the pathway *Pc* during all movements other than TH (see Fig. 1.46). In contrast

to the nearly vertical closing strokes at incisor point, the sagittal closing strokes at the molar point involve an anterior component on the working side and a posterior component on the nonworking side. This difference in molar point movement is caused by the deviation of the jaw to the working side during closure, illustrated by the difference in motion of the working-side and nonworking-side condyles. The nonworking-side closing strokes closely approach the superior border, indicating the potential for undesirable posterior tooth contact and increased elevator muscle activity (as well as increased activity of the superior lateral pterygoid muscle) on the nonworking side (see Fig. 1.46C).

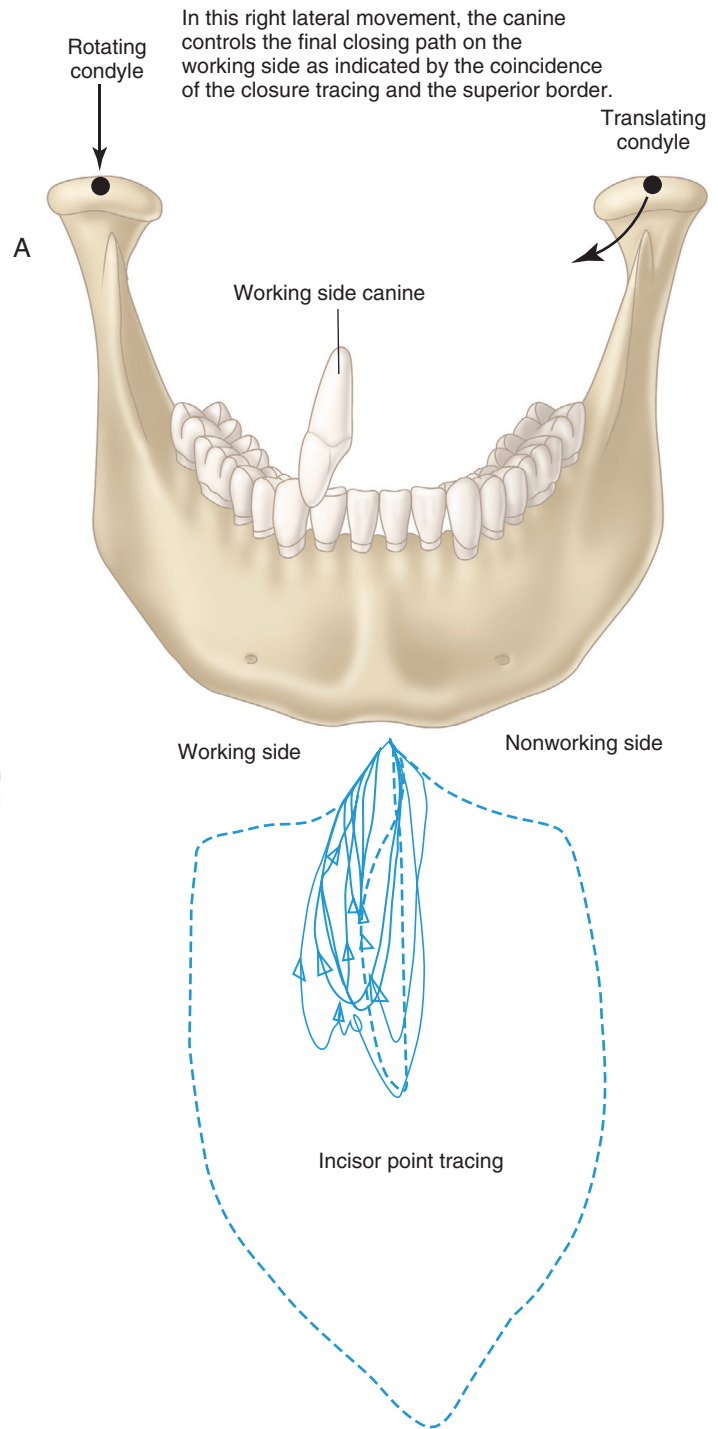
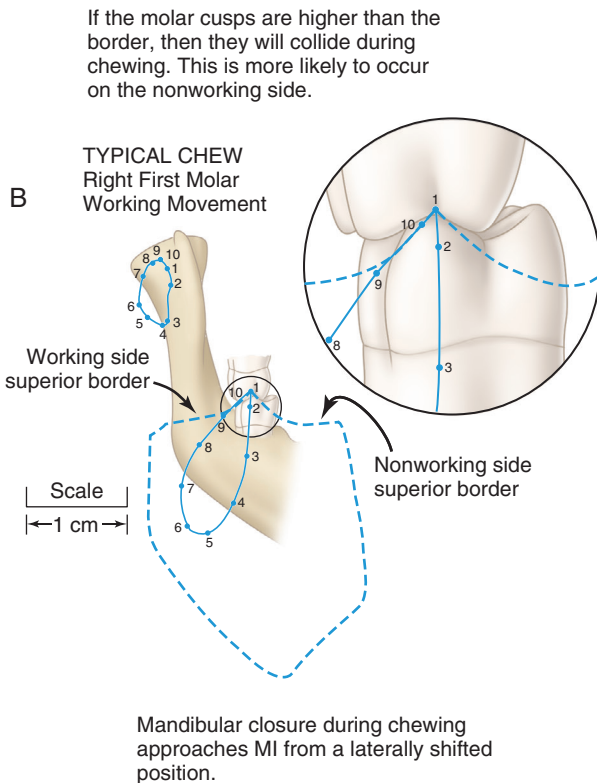
Horizontal View

Fig. 1.47A shows a horizontal view (or occlusal view when referring to teeth) of the mandible with superimposed incisor, molar, and condyle point test movements. Chewing movements are characterized by wide lateral movement of the mandible to the working side during closure (see Fig. 1.47B). When viewed from above, the pathways of the molar and incisor points are typically in a figure-8 pattern, with an S-shaped lateral opening motion and a straight medial closing stroke. Important differences exist in the directions of closure for the molar point on the working and nonworking sides. During closure on the working side (labeled *b* in Fig. 1.47B), mandibular teeth medially approach maxillary teeth from a slightly posterior position and move slightly anteriorly into MI. During closure on the nonworking side (the contralateral side, labeled *d* in Fig. 1.47B), mandibular molar teeth approach the maxillary teeth in a medial-to-lateral direction from a slightly anterior position and move slightly posteriorly into MI. The closing strokes are the same pathways generated by guided (test) lateral mandibular movements used to check the occlusion except the directions traveled are opposite (see Fig. 1.47B, *inset*). On the inset drawing of the maxillary left teeth in Fig. 1.47B, the working, nonworking, and protrusive pathways are marked *W*, *NW*, and *P*. These are the guided test movements used by dentists to assess the occlusal contact of teeth during function.

The horizontal, enlarged view of the mandible showing condyle point movement (working side labeled *a*; nonworking side labeled *e*) during chewing is important because it illustrates the lateral shift of the condyles during the closing stroke (see Fig. 1.47B). Opening, in the typical chewing motion illustrated here, involves movement of both condyle points on the midsagittal path, producing the vertical drop in the incisor point seen in the sagittal view. Lateral opening may be seen in normal children and adults with worn and flattened teeth. As closing is initiated, the mandible shifts laterally, moving both condyle points to the working side. The nonworking condyle movement closely approaches its medial border during the closing stroke (see Fig. 1.47C). During final closure, when teeth are brought into MI, the condyle points return to their starting positions. Contact and gliding on the inclines of teeth are responsible for bringing the mandible into its final, fully closed position (MI).

Allowance for lateral displacement of the condyles during lateral jaw movements is built into semiadjustable articulators in the form of a Bennett angle or progressive lateral shift adjustment. The progressive lateral shift allows the condyles to shift gradually during lateral mandibular movement. As a result of mandibular movement studies, more recent articulator models have replaced the progressive lateral shift with immediate shift. Shifting of the mandible, as depicted by the shift in the condyle points, results in a similar shift at the teeth that cannot be simulated by progressive shift (see Fig. 1.47C).

The superior border of the incisor point tracing is determined by the canine teeth, but the molar point superior border is influenced by the pathway of the condyle point. Canine guidance and articular eminence slope are mechanically coupled to produce the superior border of the molar point tracing but they do not contribute equally. The canine is primarily responsible for the superior border of molar point on the working pathway (away from the midline). The nonworking side articular eminence has the dominant influence on the nonworking pathway (toward the midline) on the molar point superior border.



Chewing movements show frequent encounters with the superior border in the incisor point tracing suggesting frequent contact of the canine teeth during closing.

• **Fig. 1.48** Mandibular capacity for movement: frontal view.

Frontal View

In **Fig. 1.48A**, lateral movement of the mandible on the superior border is controlled by three elements—the rotating condyle, the translating condyle, and the working-side canine. During chewing closures, mandibular teeth approach maxillary teeth from a lateral position. Frequent contact with the border occurs in the incisor

and molar point tracings, indicating that lateral tooth gliding is common during chewing. This gliding contact occurs on the teeth having the highest projecting cusps that form the superior border (usually canines).

The incisor point tracing is projected below the drawing of the mandible in **Fig. 1.48A**. The chewing strokes show the gliding

contact on the border. The incisor-point superior border is shaped by the lingual surfaces of the guiding teeth, which most frequently are maxillary canines. In Fig. 1.48B, the lateral side of the molar-point superior border is shaped by the working-side tooth guidance, which is usually the maxillary canine. The medial side of the molar-point superior border is predominately formed by the nonworking condyle moving down the articular eminence. The shape of the superior border at the molar point is the critical factor for determining the location and height of the molar cusps during restorative procedures. It is easy to visualize the effect of changes in the cusp height when viewing the close-up of molar teeth in the magnified inset.

Articulators and Mandibular Movements

Figs. 1.49, 1.50, 1.51, and 1.52 illustrate the scientific basis for the use of articulators to aid in diagnostic evaluation of occlusion and fabrication of dental restorations.^{37,40-42} In these figures, the characteristics of chewing movements and dentist-guided test movements are compared with the characteristics of movements produced by simple articulators. This may be done by comparing the cusp movement near MI produced by the articulator with the cusp movement observed in chewing studies or guided movements of patients. Additionally, the changes in cusp movement near MI that occur because of variations in the adjustment of articulators are discussed with respect to their effects on dental restorations.

Fig. 1.49 illustrates the relationship between condylar movement and articulator settings. Together, the horizontal condylar guidance setting and the medial-wall setting of an articulator supply sufficient information to approximate the condyle movement near MI. The horizontal condylar guidance setting approximates the slope of the articular eminence; the medial-wall setting approximates the lateral shift. Collectively, these two settings are referred to as *posterior guidance*.

Posterior guidance alone is not sufficient to simulate mandibular movements near MI because tooth guidance also is involved in forming the superior border. Full-arch casts mounted in the articulator, with the use of techniques that correctly position the maxillary cast relative to the artificial TMJs, supply the information concerning anterior guidance from canines and incisors. The mechanical coupling of the anterior guidance and posterior guidance settings provides sufficient information to simulate the movement of posterior teeth on the superior border.

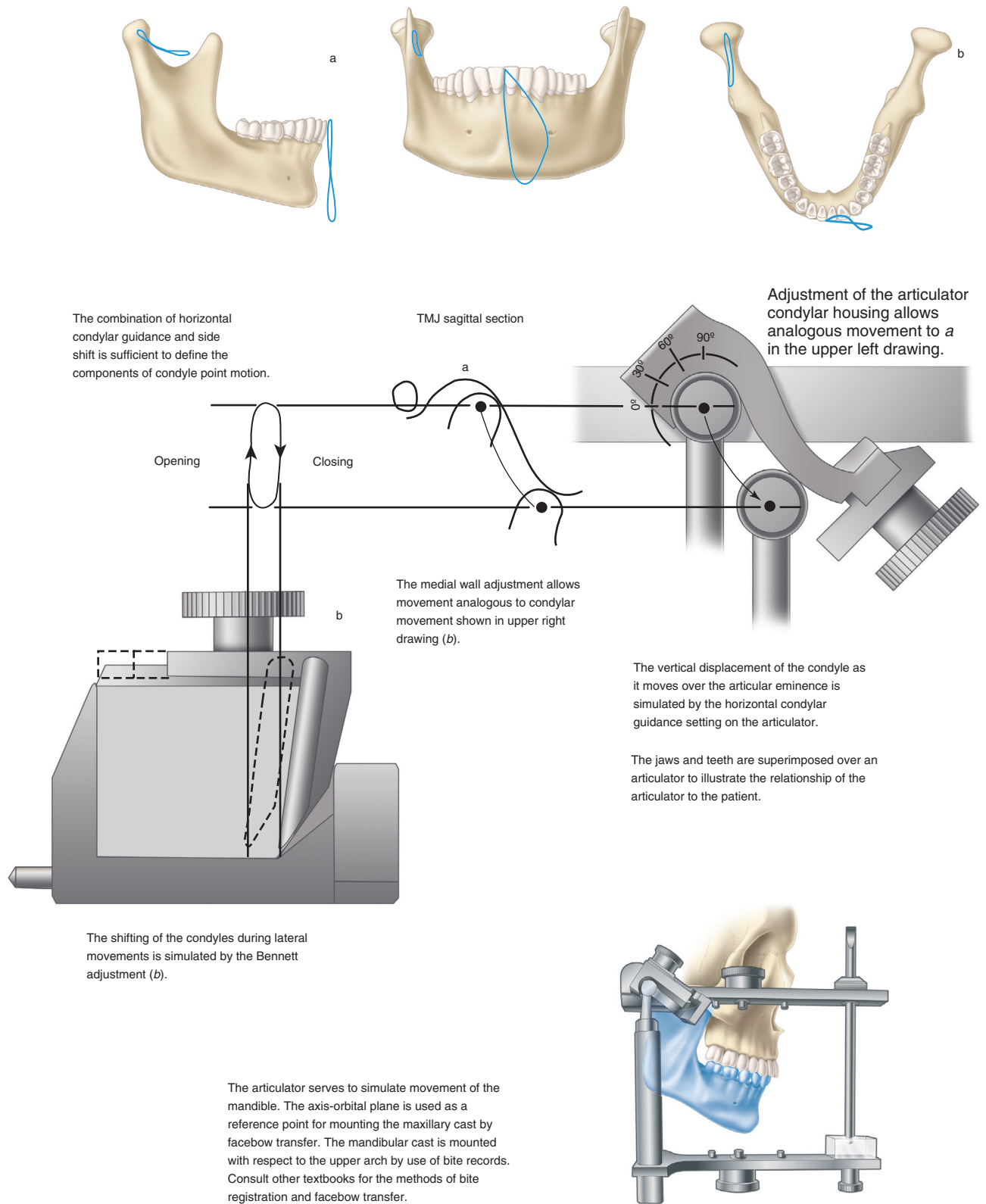
Research has identified that the slope of the articular eminence ranges approximately 25 to 70 degrees from the axis-orbital plane (see Fig. 1.50A and B).⁴³ Adjustable articulators have been designed based on these observations and allow establishment of patient-specific setting of horizontal condylar inclination. Furthermore, left/right individual settings allow for differences that may exist in the relative movements of the two condyles (see Fig. 1.50C and D). The condyles move anteriorly and inferiorly while in contact with the curved surface of the simulated articular eminence within the condylar housing of the articulator. More recent designs of semiadjustable articulators have adopted curved surfaces to simulate the curvature of the articular eminence. Only the first few millimeters of movement have significant effects on the posterior teeth. Horizontal condylar guidance (supplied by the articulator) and anterior guidance (supplied by the mounted casts) are mechanically coupled to produce the separation of posterior teeth. The combined guidance determines the amount of (or lack of) vertical separation of posterior teeth

as the mandible leaves or enters MI during protrusion and lateral movements.

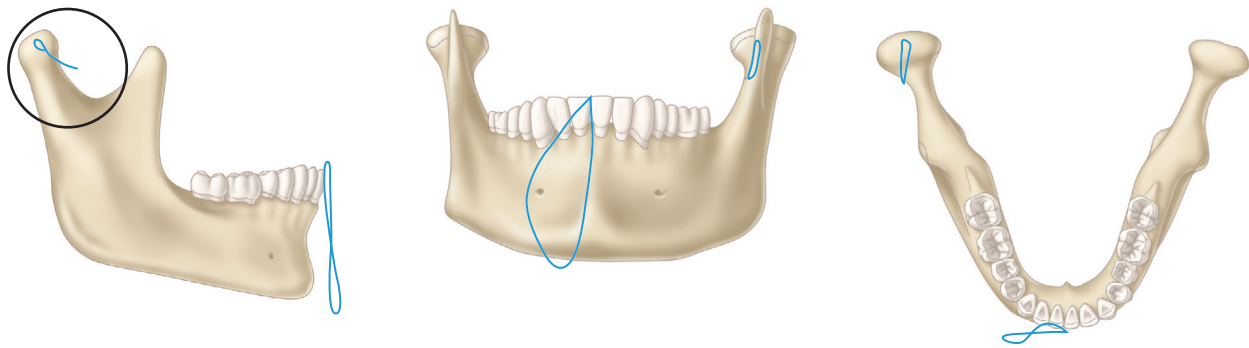
Lateral mandibular movements also produce separation of posterior teeth. Horizontal guidance of the nonworking condyle coupled with working-side canine guidance determines the amount of vertical separation of posterior teeth on both sides as the mandible leaves or enters MI during lateral movements (see Fig. 1.48). This information may be used to design restorations with the proper cusp location and height to avoid collisions during chewing and other mandibular movements.

The slope of the articular eminence varies considerably among individuals. The effect of different slopes may be evaluated by altering the horizontal condylar guidance on articulators. Increasing the horizontal condylar guidance increases the steepness of the mandibular molar movement in protrusion. The movement of the maxillary mesiolingual cusp relative to the mandibular molar is plotted in Fig. 1.50E–G for 20-, 30-, and 50-degree slopes.⁴⁴ The effect of removing the anterior guidance (*a*) is drawn on the same grid. The loss of anterior guidance has the greatest effect when the horizontal condylar guidance is shallow (20 degrees) and has the least effect when the horizontal condylar guidance is steep (50 degrees). Anterior guidance has an additive effect on the molar pathway at all degrees of horizontal guidance. This is an important observation because alteration of the anterior guidance may occur during dental treatment that involves the guiding surfaces of the anterior teeth. There may be a therapeutic advantage to increasing anterior guidance, by restorative or orthodontic means, to facilitate the separation of posterior teeth in patients who have shallow horizontal guidance. The articulator may be used to diagnose the need to alter the anterior guidance and to design restorations that avoid cusp collisions in mandibular movements.

TMJ lateral shift may be measured clinically and transferred to an adjustable articulator. A series of tracings of guided movements from different patients is shown in Fig. 1.51A.^{45,46} All the tracings are parallel after the first few millimeters of movement. The difference from one patient to the next is the result of the amount of lateral shift. Fig. 1.51B illustrates simulations of arcs at different degrees of lateral shift; the similarity of lines *a*, *b*, and *c* to the lines similarly marked in Fig. 1.51A should be noted. None of the tracings of lateral condylar movement exhibits the “progressive” lateral shift indicated by the dashed line in Fig. 1.51B. Fig. 1.51C illustrates the underside of a condylar housing of an articulator. Shifting the medial wall simulates TMJ lateral shift and allows movements similar to those illustrated in Fig. 1.51A. Fig. 1.51D illustrates how movements *a*, *b*, and *c* were made for Fig. 1.51B by shifting the medial wall of the condylar housing on the articulator. Increasing lateral shift of the TMJ results in significant changes in movement of the molar point near MI (see Fig. 1.51E). The working-side movement is least affected because it is already a directly lateral movement. The nonworking molar-point movement is changed in the lateral and horizontal components. The lateral pathway is extended progressively more laterally in patients with excessive lateral shift of the TMJs. The horizontal effect is a “flattening” of the pathway by reduction of the vertical separation. These effects are illustrated by tracings of molar-point movement on an articulator as the amount of lateral shift is increased from “*a*” to “*b*” to “*c*.” The effect of increasing lateral shift is to increase the likelihood of collisions of the mesiolingual cusps of the maxillary molars with the mandibular distofacial cusps of the molars on the nonworking side (see Fig. 1.51E and F). These types of undesirable contact between the opposing functional cusps are termed *nonworking interferences*.

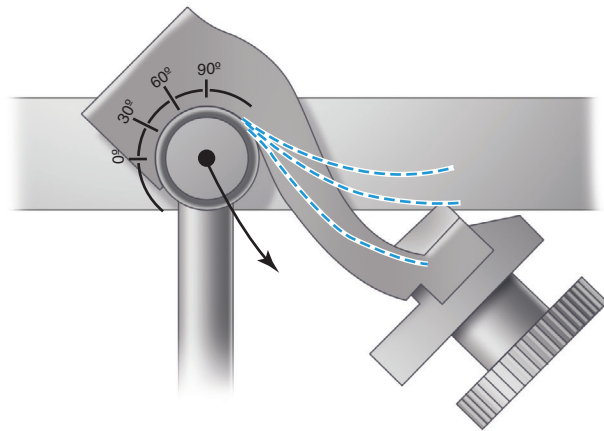
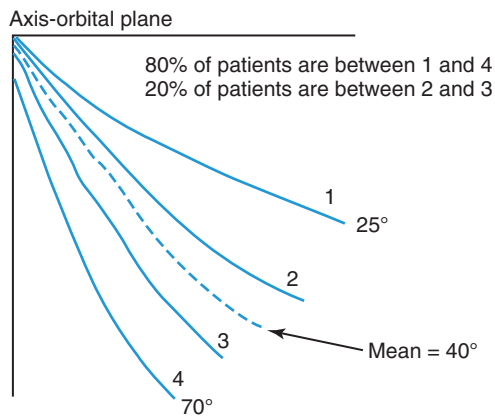


• **Fig. 1.49** Relationship between condylar movement and articulator settings.

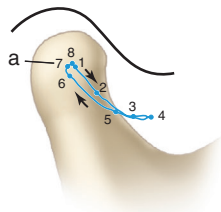


A Observed pathways

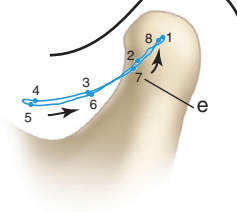
B Effect of adjustment



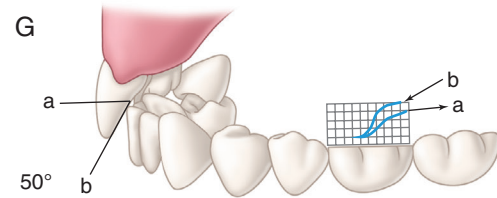
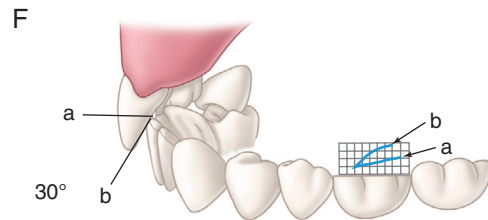
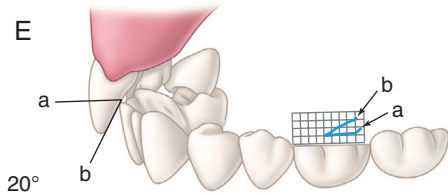
C Working condyle point (a) movement



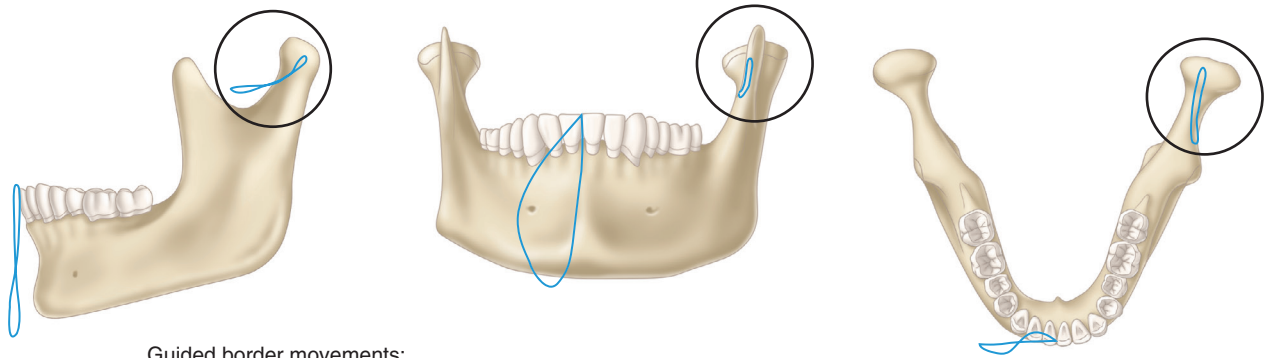
D Nonworking condyle point (e) movement



E, F, and G illustrate the combined effect of anterior and posterior guidance on the superior border of molar point. The angulation of the posterior guidance is indicated in degrees for each figure. The absence of anterior guidance is indicated by *a* and presence of anterior guidance by *b*. The tracing of the movement of the mesiolingual cusp of the maxillary molar is made on the grid in each figure. Note that the absence of anterior guidance reduces the separation of the posterior teeth, but has the greatest effect when the posterior guidance is shallow.

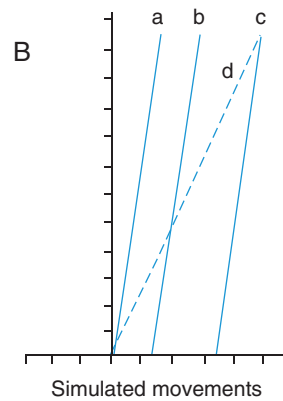
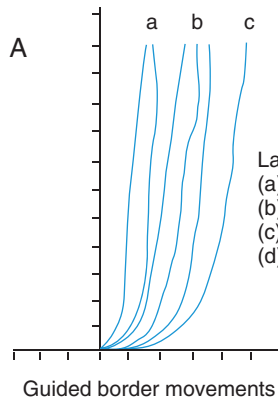


• Fig. 1.50 Horizontal condylar guidance.

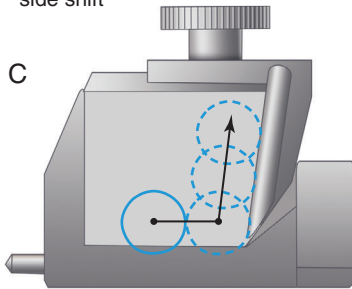


- Guided border movements:
1. Follow chewing pathway in reverse direction
 2. Differences are due to amount of side shift
 3. Progressive side shift was not observed

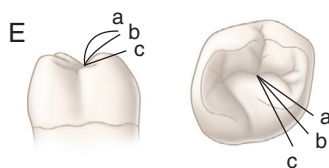
- Simulated movements:
1. Are arcs of circles
 2. Differ by side shift
 3. Are comparable to guided movements



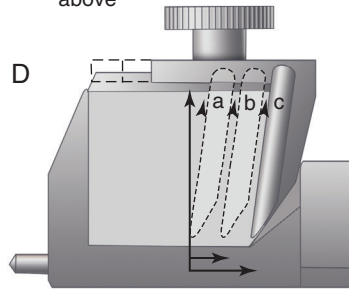
Underside of condylar housing
 condylar ball movement at extreme
 side shift



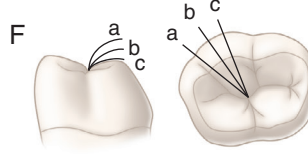
Maxillary molar; showing
 change in nonworking
 movement of mandibular
 distofacial cusp with
 increasing lateral shift



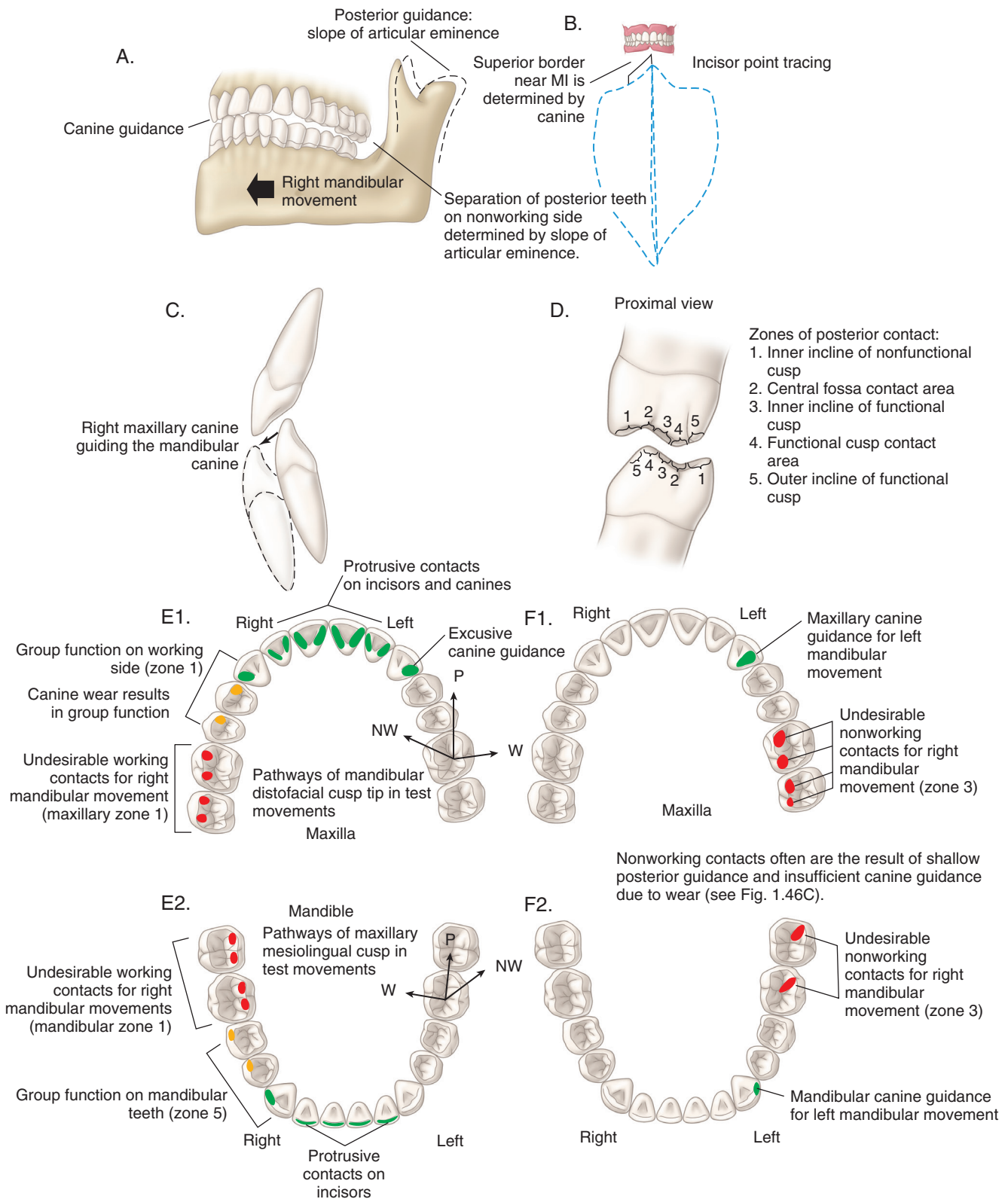
Adjustment of the lateral shift to
 produce simulated movements
 above



Mandibular molar; showing
 change in nonworking
 movement of maxillary
 mesiolingual cusp with
 increasing lateral shift



• Fig. 1.51 Lateral condylar guidance: the medial wall.



of the posterior teeth on the left, or nonworking, side. This separation of posterior teeth results from the combined effects of the canine guidance and the slope of the articular eminence on the nonworking side. The effect of the canine guidance is illustrated in the incisor point tracing in Fig. 1.52B. The superior border on either side of MI is determined by the shape of the lingual surfaces of maxillary canine teeth. Guiding contact between the right canines is illustrated in Fig. 1.52C. A variety of areas on posterior teeth may contact opposing teeth during mandibular movements. In Fig. 1.52D, the opposing surfaces of molar teeth are divided into five areas:

1. *Inner incline of the nonfunctional cusp.* This area has the potential for undesirable contact in working-side movements by contacting the outer aspect of the functional cusp (area 5).
2. *Fossa or marginal ridge contact area.* This is the main contact area for the opposing functional cusp.
3. *Inner incline of the functional cusp.* This area has the potential for undesirable contact during nonworking movements.
4. *Contact area of the functional cusp.* This is the main cusp contact area.
5. *Outer aspect of the functional cusp.* This area sometimes participates in working-side movements by contacting the inner incline of the nonfunctional cusp (area 1).

Anterior Tooth Contacts

During anterior movement of the mandible (i.e., protrusion), the lower anterior teeth glide along the lingual surfaces of maxillary anterior teeth (see Fig. 1.52E and F). The combination of the anterior guidance (slope and vertical overlap of anterior teeth) and the slope of the articular eminence (horizontal condylar guidance on the articulator) determines the amount of vertical separation of posterior teeth as the mandible moves anteriorly. Some texts refer to this separation as *disocclusion* (or *disclusion*) of posterior teeth. Multiple contacts between the opposing dental arches on anterior teeth are desirable in protrusion movements. With protrusion, multiple contacts serve to prevent excessive force on any individual pair of gliding teeth. Posterior tooth contact during protrusion is not desirable because it may overload the involved teeth secondary to the increased elevator muscle activity that occurs when posterior teeth come into contact. It has been shown that when anterior teeth are in contact and posterior teeth are discluded, elevator muscles are less active.^{16-19,23,27,30,47}

Articulator-mounted casts may be used to assess the superior border near MI, which is the critical zone for tooth contact. This information is useful during the fabrication of indirect restorations because the position and height of the restored cusps can be evaluated and adjusted in the laboratory, which minimizes the chairside time and effort required to adjust the completed restorations.

Posterior Tooth Contacts

In idealized occlusal schemes designed for restorative dentistry, posterior teeth should contact only in MI such that the force that results from maximum activation of the elevator muscles is distributed evenly over multiple teeth.^{16-19,23,27,28,30,47} Any movement of the mandible should result in the separation of posterior teeth by the combined effects of anterior guidance and the slope of the articular eminence (horizontal condylar guidance on the articulator). The immediate separation of posterior teeth during protrusion or excursion results in a decrease in the level of activity and force being generated by the elevator muscles.^{16,18,19,21,23,27,30,47}

Forceful contact of individual posterior tooth cusps during chewing and clenching may lead to muscle discomfort, damage

to teeth and supporting structures, or both in some patients. In patients with shallow anterior guidance or open bite, restoration without the introduction of undesirable tooth contacts is more difficult. Articulator-mounted casts may be used to assess and solve restorative problems that are difficult to manage by direct intraoral techniques.

The preferred occlusal relationship for restorative purposes is one that limits the working-side contact to canines only. This is directly related to the observation that, compared with canine guidance alone, guidance from canines *and* posterior teeth will result in greater activation of the anterior temporalis muscle and longer activation of the masseter and temporalis muscles during excursive movements.^{27,30,47}

Tooth contact posterior to the canine on the working side may occur naturally in worn dentitions. As canines are shortened by wear, separation of posterior teeth diminishes. Lateral mandibular movements in worn dentitions successively bring into contact more posterior teeth as the heights of canines decrease. Multiple tooth contacts during lateral jaw movements are termed *group function*. Right-sided group function is illustrated in Fig. 1.52E, compared with left canine guidance contact in Fig. 1.52F. Because the amount of torque and wear imposed on teeth increases closer to the muscle attachments on the mandible, molar contact in group function is undesirable (see Fig. 1.52E and F). It has been observed that facial cusps of the maxillary premolars and molars (Maxillary Zone 1, nonfunctional cusps) and lingual cusps of mandibular molars (Mandibular Zone 1, nonfunctional cusps) have increased incidence of fracture.⁴⁸ This finding is consistent with the increased elevator muscle activity that occurs as posterior teeth come into contact and that the bulk of dentin supporting the nonfunctional cusps is considerably less than that of the functional maxillary and mandibular cusps. Group function limited to premolars may be a therapeutic goal when the bony support of canines is compromised by periodontal disease or Class II occlusions in which canine guidance is impossible.

The nonworking side is opposite the working side and normally does not contain a food bolus during chewing. During chewing closures, mandibular teeth on the nonworking side close from an anteromedial position and approach MI by moving posterolaterally. Contact of the molar cusps on the nonworking side may overload these teeth, compromise the ipsilateral TMJ, or both because of a resultant increase in the activity of the masseter, anterior temporalis, and posterior temporalis muscles and the ipsilateral superior lateral pterygoid.^{16-18,20} Each of these muscles counteracts the action of the nonworking-side inferior lateral pterygoid, which is responsible (along with the contralateral posterior temporalis and digastric muscles) for effecting the down and forward translation of the nonworking-side condyle. Additional activity of the ipsilateral superior lateral pterygoid muscle should not occur during condylar translation when the TMJ disc needs to rotate posteriorly toward the top of the condylar head to maintain its position between the condyle and the articular eminence. Great variation exists among patients in the level of masticatory system tolerance to nonworking-side contacts. Questions remain as to whether the presence of a nonworking-side posterior contact always represents an interference to mandibular function. The predictable, normal physiologic muscle response to nonworking-side tooth contact (along with the potential negative sequelae of tooth wear, tooth fracture, masticatory muscle pain and/or TMJ internal disc derangement) leads to the conclusion that avoidance of these contacts is an important goal for restorative procedures in the posterior dentition. Undesirable nonworking-side contacts are illustrated in Fig. 1.52F.

Neurologic Correlates and Control of Mastication

This summary of neurologic control is based on an excellent review by Lund.⁴⁹ The control of mastication depends on sensory feedback. Sensory feedback serves to control the coordination of the lips, tongue, and mandibular movement during manipulation of the food bolus through all stages of mastication and preparation for swallowing. Physiologists divide an individual chewing cycle into three components: *opening*, *fast closing*, and *slow closing*. The slow-closing segment of chewing is associated with the increased forces required for crushing food. The central nervous system receives several types of feedback from muscle spindles, periodontal receptors, and touch receptors in the skin and mucosa. This feedback controls the mandibular closing muscles during the slow-closing phase. Sensory feedback often results in inhibition of movement (e.g., because of pain). During mastication, some sensory feedback from teeth is excitatory, causing an increase in the closing force as the food bolus is crushed. An upper limit must, however, be present where inhibition occurs; this prevents the buildup of excessive forces on teeth during the occlusal stage.

A group of neurons in the brainstem produces bursts of discharges at regular intervals when excited by oral sensory stimuli. These bursts drive motor neurons to produce contractions of the masticatory muscles at regular intervals, resulting in rhythmic mandibular movement. The cluster of neurons in the brainstem that drives the rhythmic chewing is termed *central pattern generator*. The chewing cycles illustrated in Figs. 1.46, 1.47, and 1.48 are caused by central pattern generator rhythms. Oral sensory feedback can modify the basic central pattern generator pattern and is essential for the coordination of the lips, tongue, and mandible. Sensory input from the periodontal and mucosal receptors maintains the rhythmic chewing. Coactivation of the opening and closing muscles serves to protect the dentition from excessively forceful contact, makes the mandible more rigid, and probably serves to brace the condyles while the food is crushed.

References

- Dusevich V, Xu C, Wang Y, et al: Identification of a protein-containing enamel matrix layer which bridges with the dentin-enamel junction of adult human teeth. *Arch Oral Biol* 57(12):1585–1594, 2012.
- Digka A, Lyroudia K, Jirasek T, et al: Visualisation of human dental pulp vasculature by immunohistochemical and immunofluorescent detection of CD34: a comparative study. *Aust Endod J* 32:101–106, 2006.
- Garberoglio R, Brännström M: Scanning electron microscopic investigation of human dentinal tubules. *Arch Oral Biol* 21:355–362, 1976.
- Scott JH, Symons NBB: *Introduction to dental anatomy*, ed 9, Philadelphia, 1982, Churchill Livingstone.
- Craig RG, Powers JM: *Restorative dental materials*, ed 12, St Louis, 2006, Mosby.
- Brännström M: *Dentin and pulp in restorative dentistry*, London, 1982, Wolfe Medical.
- Michelich V, Pashley DH, Whitford GM: Dentin permeability: comparison of function versus anatomic tubular radii. *J Dent Res* 57:1019–1024, 1978.
- Sturdevant JR, Pashley DH: Regional dentin permeability of class I and II cavity preparations (abstract no. 173). *J Dent Res* 68:203, 1989.
- Farges J-C, Alliot-Licht B, Renard E, et al: Dental pulp defence and repair mechanisms in dental caries. *Mediat Inflamm* 2015. <http://dx.doi.org/10.1155/2015/230251>. Article ID 230251.
- Boushell LW, Nagaoka H, Nagaoka H, et al: Increased matrix metalloproteinase-2 and bone sialoprotein response to human coronal caries. *Caries Res* 45:453–459, 2011, doi:10.1159/000330601.
- Mohl ND, Zarb GA, Carlsson GE, et al: The dentition. In Mohl ND, Zarb GA, Carlsson GE, et al, editors: *A textbook of occlusion*, Chicago, 1988, Quintessence.
- Gibbs CH, Messerman T, Reswick JB, et al: Functional movements of the mandible. *J Prosthet Dent* 26(5):604–620, 1971.
- Angle EH: Classification of malocclusion. *Dent Cosmos* 41:248–264, 350–357, 1899.
- Kraus BS, Jordan E, Abrams L: *Dental anatomy and occlusion*, ed 1, Baltimore, 1969, Williams & Wilkins.
- Dawson PE: *Functional occlusion: from TMJ to smile design*, St Louis, 2007, Mosby.
- Belser UC, Hannam AG: The influence of altered working-side occlusal guidance on masticatory muscles and related jaw movement. *J Prosthet Dent* 53(3):406–413, 1985.
- Gibbs CH, Mahan PE, Wilkinson TM, et al: EMG activity of the superior belly of the lateral pterygoid muscle in relation to other jaw muscles. *J Prosthet Dent* 51(5):691–702, 1984.
- Vitti M, Basmajian JV: Integrated actions of masticatory muscles: simultaneous EMG from eight intramuscular electrodes. *Anat Rec* 187:173–190, 1976.
- Williamson EH, Lundquist DO: Anterior guidance: its effect on electromyographic activity of the temporal and masseter muscles. *J Prosthet Dent* 49(6):816–823, 1983.
- Santana U, Mora MJ: Electromyographic analysis of the masticatory muscles of patients after complete rehabilitation of occlusion with protection by non-working side contacts. *J Oral Rehabil* 22:57–66, 1995.
- Valenzuela S, Baeza M, Miralles R, et al: Laterotrusive occlusal schemes and their effect on supra- and infrahyoid electromyographic activity. *Angle Orthod* 76(4):585–590, 2006.
- Mahan PE, Wilkinson TM, Gibbs CH, et al: Superior and inferior bellies of the lateral pterygoid muscle and EMG activity at basic jaw positions. *J Prosthet Dent* 50(5):710–718, 1983.
- Borromeo GL, Suvinen TI, Reade PC: A comparison of the effects of group function and canine guidance interocclusal device on masseter muscle electromyographic activity in normal subjects. *J Prosthet Dent* 74(2):174–180, 1995.
- Graham GS, Rugh JD: Maxillary splint occlusal guidance patterns and electrographic activity of the jaw-closing muscles. *J Prosthet Dent* 59(1):73–77, 1988.
- Hannam AG, De Cou RE, Scott JD, et al: The relationship between dental occlusion, muscle activity and associated jaw movement in man. *Arch Oral Biol* 22:25–32, 1977.
- Leiva M, Miralles R, Palazzi C, et al: Effects of laterotrusive occlusal scheme and body position on bilateral sternocleidomastoid EMG activity. *J Craniomandibular Practice* 21(2):99–109, 2003.
- Manns A, Chan C, Miralles R: Influence of group function and canine guidance on electromyographic activity of elevator muscles. *J Prosthet Dent* 57(4):494–501, 1987.
- Manns A, Miralles R, Valdivia J, et al: Influence of variation in anteroposterior occlusal contacts on electromyographic activity. *J Prosthet Dent* 61:617–623, 1989.
- Rugh JD, Drago CJ: Vertical dimension: a study of clinical rest position and jaw muscle activity. *J Prosthet Dent* 45(6):670–675, 1981.
- Shupe RJ, Mohamed SE, Christensen LV, et al: Effects of occlusal guidance on jaw muscle activity. *J Prosthet Dent* 51(6):811–818, 1984.
- Huang BY, Whittle T, Peck CC, et al: Ipsilateral interferences and working-side condylar movements. *Arch Oral Biol* 51:206–214, 2006.
- Solberg WK, Woo MW, Houston JB: Prevalence of mandibular dysfunction in young adults. *J Am Dent Assoc* 98:25–34, 1979.
- Posselt U: Studies in the mobility of the mandible. *Acta Odont Scand* 10(Suppl 10):1952.

34. Gibbs CH, Lundeen HC: Jaw movements and forces during chewing and swallowing and their clinical significance. In Lundeen HC, Gibbs CH, editors: *Advances in occlusion*, Bristol, 1982, John Wright PSG.
35. Celenza FV, Nasedkin JN: *Occlusion: the state of the art*, Chicago, 1978, Quintessence.
36. Keshvad A, Winstanley RB: An appraisal of the literature on centric relation. *J Oral Rehabil* 28:55–63, 2001.
37. Crawford SD: Condylar axis position, as determined by the occlusion and measured by the CPI instrument, and signs and symptoms of temporomandibular dysfunction. *Angle Orthod* 69(2):103–116, 1999.
38. Landi N, Manfredini D, Tognini F, et al: Quantification of the relative risk of multiple occlusal variables for muscle disorders of the stomatognathic system. *J Prosthet Dent* 92:190–195, 2004.
39. Pahkala R, Qvarnstrom M: Can temporomandibular dysfunction signs be predicted by early morphological or functional variables? *Eur J Orthod* 26(4):367–373, 2004.
40. Griffiths RH: Report of the president's conference on the examination, diagnosis, and management of temporomandibular disorders. *J Am Dent Assoc* 106:75–77, 1983.
41. Kim SK, Kim KN, Chang IT, et al: A study of the effects of chewing patterns on occlusal wear. *J Oral Rehabil* 28:1048–1055, 2001.
42. Mongelli de Fantini S, Batista de Paiva J, Neto JR, et al: Increase of condylar displacement between centric relation and maximal habitual intercuspation after occlusal splint therapy. *Braz Oral Res* 19(3): 176–182, 2005.
43. Lundeen HC, Wirth CG: Condylar movement patterns engraved in plastic blocks. *J Prosthet Dent* 30:866–875, 1973.
44. Lundeen HC, Shryock EF, Gibbs CH: An evaluation of mandibular border movements: their character and significance. *J Prosthet Dent* 40:442–452, 1978.
45. Lundeen TF, Mendosa MA: Comparison of Bennett shift measured at the hinge axis and an arbitrary hinge axis position. *J Prosthet Dent* 51:407–410, 1984.
46. Lundeen TF, Mendosa MA: Comparison of two methods for measurement of immediate Bennett shift. *J Prosthet Dent* 51:243–245, 1984.
47. Akoren AC, Karaagaciloglu L: Comparison of the electromyographic activity of individuals with canine guidance and group function occlusion. *J Oral Rehabil* 22:73–77, 1995.
48. Bader JD, Martin JA, Shugars DA: Incidence rates for complete cusp fracture. *Comm Dent Oral Epidemiol* 29:346–353, 2001.
49. Lund JP: Mastication and its control by the brain stem. *Crit Rev Oral Biol Med* 2:33–64, 1991.